



Meniscal injury rate and its clinical outcome in the knee fracture dislocation

Hossein Aslani¹, Ali Tabrizi*², Mir Bahram Safari²

¹ Department of Orthopedic, Shohada Educational Hospital, Tabriz University of Medical Sciences, Tabriz, Iran

² Clinical Research Development Unit of Imam Khomeini Hospital, Urmia University of Medical Sciences, Urmia, Iran

*Corresponding authors: Ali Tabrizi, Address: Clinical Research Development Unit of Imam Khomeini Hospital, Urmia University of Medical Sciences, Urmia, Iran , Email: Dr.tabrizi.ali@hotmail.com, Tel: +989143130829

Abstract

Background & Aims: Treating fracture-dislocation of the knee is very complex and it is associated with several complications. Soft tissue damages are very common and ignoring them may affect the treatment results. The present study aimed at evaluating the incidence rates and the effect of meniscal injuries on the fracture-dislocation of the knee.

Materials and Methods: In this retrospective-descriptive analytical study, 25 patients suffering from fracture-dislocation of the knee with types II-V damages, according to the Moore classification criterion, underwent open reduction, fracture fixation, and meniscal repair or debridement process. They were followed-up for two years.

Results: Anatomic reduction of articular surface was obtained in 95% of the cases. The joint range of motion (ROM) was near to normal in 70% of the cases, 25% of the patients experienced functional ROM following manipulation, and 5% of cases required quadricepsplasty. Meniscal damages were observed in all cases (100%). The mean Lysholm score was 65±3.2 in the patients who were treated with meniscal debridement, whereas in patients who underwent meniscal repair, mean lysholm score was significantly higher (76.4±4.6) (P=0.001). Painful knee was observed in 16 patients (64%), and the majority of patients who had their meniscus were debrided.

Conclusions: Meniscal damage is observed in all cases with knee dislocation fracture requiring repair or debridement. Reconstruction of the damaged meniscus plays an important role in the clinical outcome of patients.

Keywords: Knee dislocation fracture, Meniscal damage, Tibial plateau fractures

Received 17 May 2019; accepted for publication 23 July 2019

Introduction

Knee dislocation accounts for 0.02-0.2% of orthopedic damages. Although it is not more common, it should be considered due to its importance (1,2). It often occurs in youths, because of the accidents or falls. 3 out of 4 stable knee ligaments are ruptured due to the knee dislocation(3). The most important known

complications of knee dislocation are vascular and neural damages as well as the fractures caused by knee dislocation (4). According to the Moore TM, knee dislocation-fractures are more acute than tibial plateau fractures, which should be highly considered (5,6).

It has been shown that different knee tissues are located improperly and damaged in the knee dislocation-

fracture. In posterolateral cases, the reduction is not successful due to the improper locating and trapping of the medial capsule, retinaculum, medial meniscus, and vastus medialis at the dislocated knee area (7). Meniscal damage can be seen in tibial plateau fractures, and knee dislocation is an important challenge for orthopedic surgeons (8,9). It has been reported that meniscus rupture is more likely to be observed in tibial plateau fractures. On the other hand, meniscal damages are regarded as one of the most important factors leading to posttraumatic arthritis and a significant decrease in the knee joint function (10, 11).

It is crucial to appropriately treat, repair, or debride the damaged meniscus for stabilizing knee joint, congruency, and the minimum level of articular contact pressure (12). Only few studies have attempted to determine the meniscal damages in knee complex dislocations fractures. This study aimed to investigate the incidence rate of meniscal injuries and its effect in the knee dislocations fractures.

Methods

This retrospective descriptive-analytical study was conducted at the educational-therapeutic center of the Tabriz University of Medical Sciences, as the center for traumatic patients in the northwest of Iran. Inclusion criteria included the traumatic patients with fracture-dislocation of the knee due to high-energy trauma. Patients who had open knee injuries, limb crush or soft tissue damage, and signs of vascular injury (such as active hemorrhage, expanding hematoma, and distal ischemia who should inform the therapist for immediate vascular imaging), previous knee deformities, systemic disease (diabetes, rheumatoid arthritis, etc.), and smokers were excluded. Twenty five traumatic patients suffering from types II-V knee dislocation-fracture, according to the Moore TM classification of fracture-dislocations of the tibial plateau (Type I: coronal split fracture of the medial tibial plateau; Type II: entire condyle; Type III: rim avulsion; Type IV: rim compression; Type V: four-part fracture) were studied (13). Initially, physical examination was done for all patients, followed by conventional radiography and

computed tomography (CT) imaging (Figure 1). The patients were treated through open reduction and internal fixation with combined posteromedial and extended anterolateral approach when the medial side needed fixation. A longitudinal incision measuring approximately 12-15 cm was placed on the anterolateral aspect of the knee. Anterolateral arthrotomy was done and the meniscal injuries were determined. The incidence rate of the resulted meniscal damages was clinically evaluated through the operation (Figure 2). A 4.5 inch proximal anatomical locking plate was used for fractures fixation in the lateral side and a 3.5 inch reconstruction plate for the medial side, if needed. The meniscal repair was done with a non-absorbable Fiber wire suture. All operations were performed by two orthopedic trauma fellowship-trained surgeons. All patients were followed up for two years. The final functional score of the patients was determined using the Lysholm Knee Scale Scoring system. The rehabilitation program was similar in 25 patients with knee fracture-dislocations.

Statistical analysis:

Data analysis was done using MedCalc software. Descriptive statistical analysis (No. (%), mean±standard deviation), and the Independent T-test (for comparison of the quantitative variables) were used.

Results

In this study, 25 traumatic patients who suffered from knee dislocation fracture including 19 males (76%) and 6 females (24%) with a mean age of 32±10.5 years were studied. According to the Moore TM classification, 11 (44%), 4 (16%), and 10 (40%) patients had type V, III, and II knee dislocation-fracture, respectively. Meniscal damages were observed in all cases through the operation. The lateral meniscus was observed in 14 (56%) patients, both meniscus in 4 (16%) patients, and ruptured medial meniscus in 7 (28%) patients. It was not possible to maintain or repair the meniscal rupture in 12 patients (48%), due to its high severity, so it was debrided. The damaged meniscus was maintained and repaired in 13 (52%) cases. Vertical ruptures of the posterior and anterior branches of the lateral meniscus

were regarded as the most common type of rupture, which was observed in 8 (40%) patients. Contusion damages and horizontal ruptures were reported in 20 (80%) cases and 3 (12%) cases, respectively. Radial or flop-shape rupture was observed in 6 (24%) patients.

Open reduction was successful in 24 (96%) patients and the anatomic reduction was not obtained in one case. No related vascular damage which needs vessels surgical intervention was reported, whereas peroneal nerve damage was observed in 7 (28%) patients. In the follow-up, 2 patients (8%) had peroneal nerve recovery, whilst other patients used ankle support and physiotherapy. Ligament injuries were observed in most patients so that medial collateral ligament (MCL), lateral collateral ligament (LCL), and posterior cruciate ligament (PCL) failed and anterior cruciate ligament

(ACL) was intact in 4(16%) patients. In 5 (20%) patients, ligament injuries delayed reconstruction.

During follow-up, range of motion (ROM) was 110 ± 25 degrees in 18 (72%) patients, and 7 (28%) patients experienced functional ROM following manipulation. There was one case (4%) of deep and one case (4%) of superficial infection. The mean Lysholm score was 65 ± 3.2 in the patients who were treated with meniscal debridement, whereas in patients who underwent meniscal repair, the mean lysholm score was significantly higher (76.4 ± 4.6) ($p=0.001$). In the follow-up, the painful knee was observed in 16 (64%) patients, and the majority of patients, who had their meniscus, were debrided. Figures 1 and 2 show the clinical photography through the operation and radiography of the patients to the associated meniscal damage.

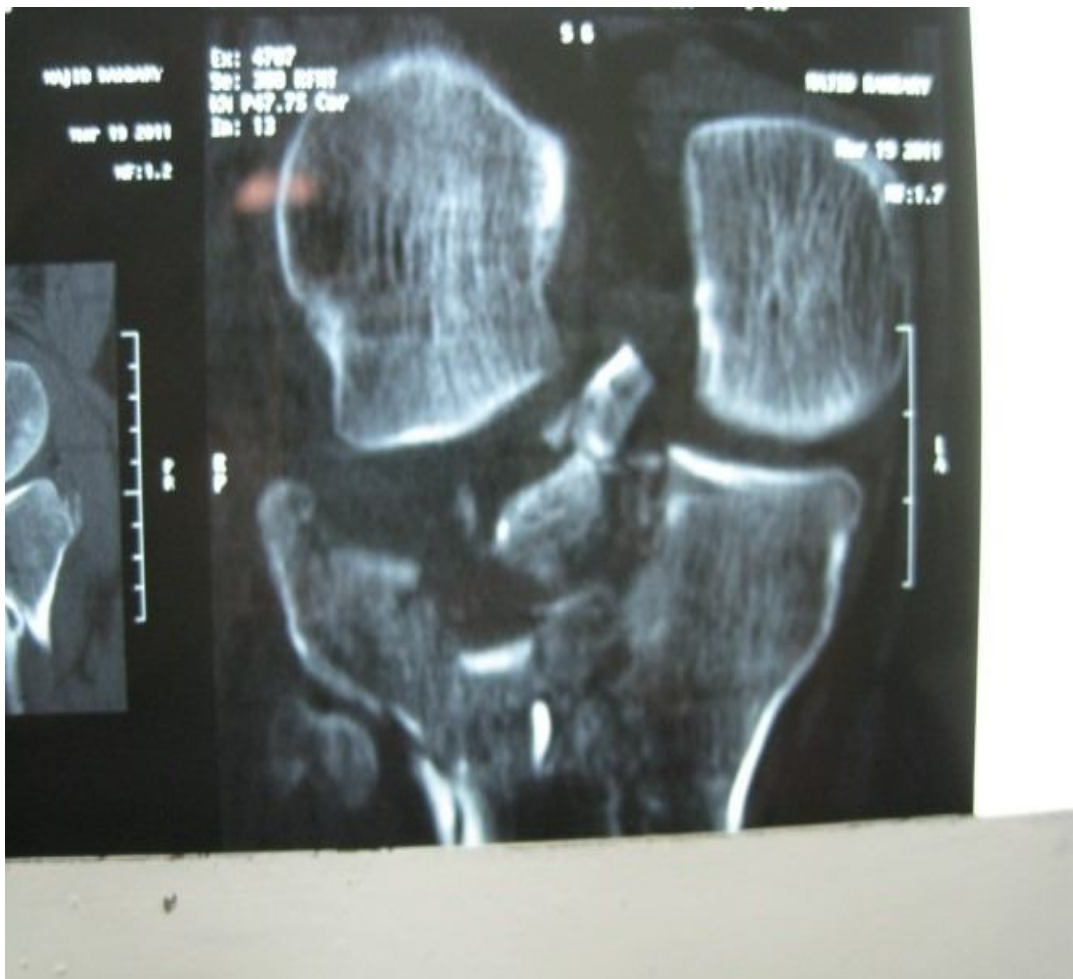

Fig 1A. CT-Scan of a patient with both meniscuses ruptures in the Knee fracture-

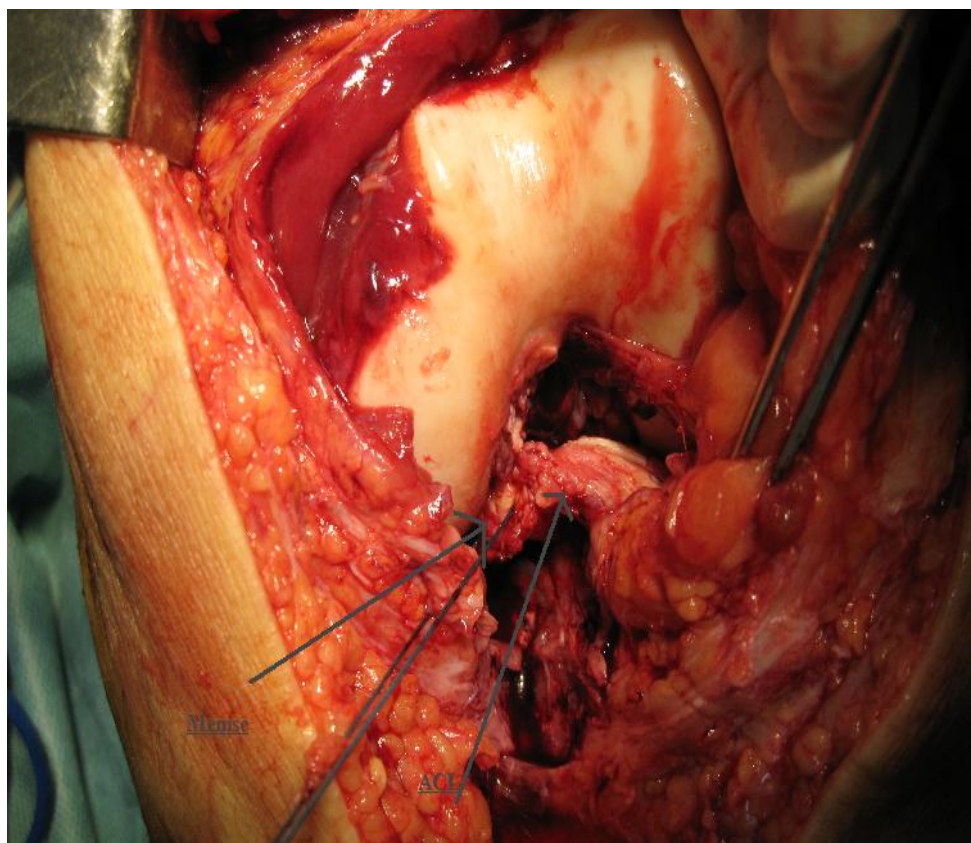


Fig 1B. CT-Scan of a patient with both meniscuses ruptures in the Knee fracture-dislocation

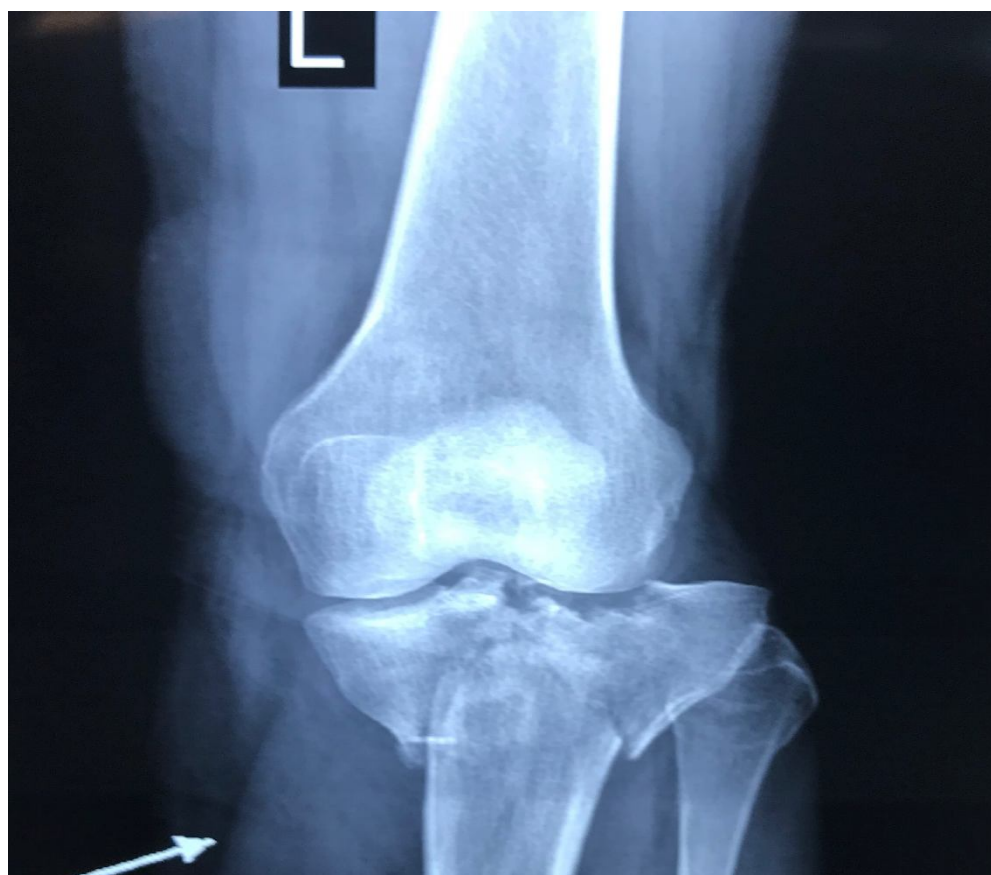


Fig 2A. Tibia bi-condylar plateau fracture and the knee dislocation associated with sever lateral meniscus rupture

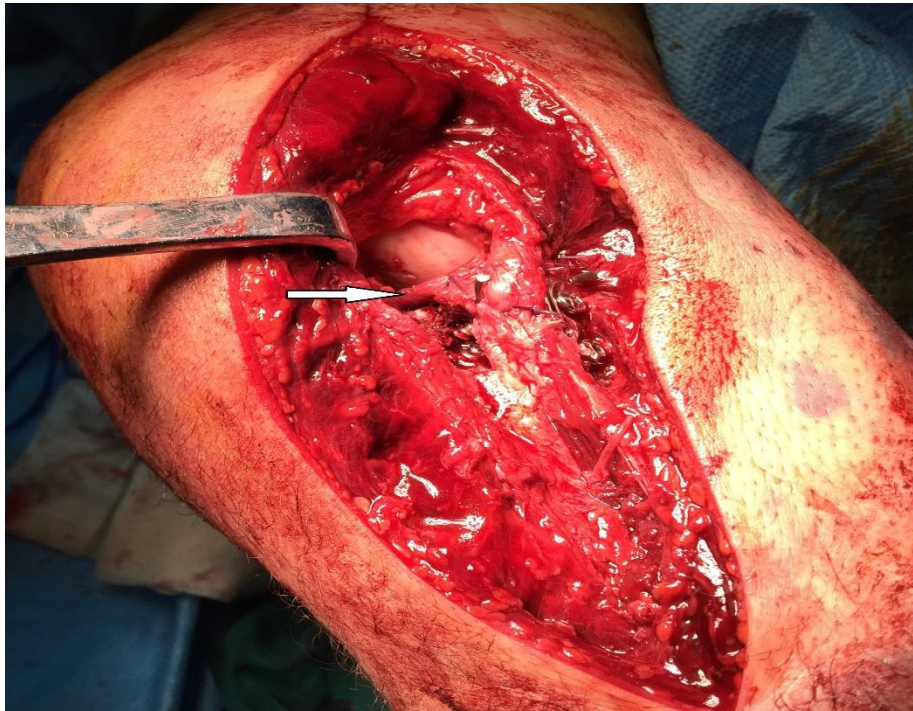


Fig 2B. Tibia bi-condylar plateau fracture and the knee dislocation associated with sever lateral meniscus rupture

Discussion

Knee dislocation fracture resulting from high-energy traffic accidents and falls is associated with a high prevalence of soft tissue damage (14,15). This type of dislocation fracture can occur in young people and affect their present and future lives. Traumatic knee dislocations and fracture-dislocations are serious injuries that require significant consideration. Initial management entails immediate closed reduction and temporary stabilization by the operative or non-operative means (30). Treatment procedures and the exact diagnosis of the associated damages, including vascular and neural damages as well as damage to the knee soft tissue, such as ligaments and menisci are of high importance and affect clinical outcomes (16,17). It is not possible to study meniscal damages, due to the severe pain and inflammation of the knee in traumatic patients at the acute phase. The damages are not often considered seriously. Imaging methods, such as magnetic resonance imaging (MRI) may be helpful in this regard. Patients with knee dislocation-fracture require more quick treatment measures and there is not enough time for imaging (18). The most important causes of knee dislocation-fracture are motor vehicle

accidents and falls (19). In the studied patients, high-energy accidents were introduced as the most important factors leading to knee dislocation-fracture. Moore et al. examined 132 patients with fracture-dislocations of the knee involving the tibial plateau. Based on their 5-group classification system, they concluded that all types were characteristically associated with joint instability and a high incidence of soft tissue and neurovascular injury (31).

Stannard et al. examined 66 patients suffering from tibial plateau fracture and they reported that the incidence rate of meniscal rupture is 49%, and Schatzker type VI fractures had the highest rate (20). Gardner et al. studied meniscal damage in patients with the tibial plateau fractures using MRI. According to their results, meniscal rupture was completely seen in 77% of the subjects and some pathology was observed in the lateral meniscus of 91% of the patients (21). In the study conducted by Mustanen et al., 42% of trauma patients with tibial plateau fracture suffered from meniscal rupture. The unstable rupture was observed in all cases (18). Meniscal rupture was seen in about 80% of the cases and the tibial plateau fractures were evaluated using MRI and they were treated with non-operative

methods (22). Vangsess et al. used arthroscopy to evaluate tibial plateau fractures, and 47% of the meniscal damages required surgical treatment (23). In the present study, meniscal rupture was clinically seen in all patients suffering from fracture-dislocation of the knee and treated surgically, which was significantly higher than the isolated tibial plateau fractures introduced in the previous studies. Meniscal rupture should be specially considered, since it may affect the clinical outcome of the patients. Lateral meniscus is the most common type of ruptures.

Open reduction of knee with complex dislocation and fracture was successfully conducted in most cases, and meniscus repair was used in some of the cases. Desirable results were obtained and no complications were reported. Near to normal joint ROM was observed in most of the patients through the follow-up. Different factors are involved in obtaining joint ROM. It is important to note that normal motion range can be obtained through anatomic reduction and repairment of the damaged ligaments or other soft tissues (24,25). Manipulation was required for anesthetized patients, where transarticular pins were used to maintain stability of the joint. However, no complications were recorded due to the transarticular pins, such as infection, and desirable results were obtained. In previous studies, the mean reported incidence of arthrofibrosis is about 29%. It was recorded 38% in the 5-year evaluations of the patients (26-29). The mean Lysholm score was 75, which is similar to the previous studies, indicating a successful surgical intervention in the open reduction of the patients.

Conclusion

In addition to the ligament ruptures, meniscal damages which are highly prevalent in the knee dislocation-fracture and can be seen in most patients should be specially considered. Favorable results were obtained by anatomic open reduction of the articular surface and meniscus reconstruction.

Acknowledgments:

This study was financially supported by the Tabriz University of Medical sciences.

Conflict of interest:

None declared.

References

1. Yeh W.L, Tu Y.K, Su J.Y, Hsu R.W, Knee dislocation: treatment of high-velocity knee dislocation. *J Trauma* 1999; 4:693–701.
2. Yu J.S, Goodwin. D, Salonen D. Complete dislocation of knee: spectrum of associated soft-tissue injuries depicted by MR imaging. *AJR Am J Roentgenol* 1995; 16:135–9.
3. Howells N.R. , Brunton L.R, Robinson J, Porteus A.J, Eldridge J.D, Murray J.R. Acute knee dislocation: An evidence based approach to the management of the multiligament injured knee. *Injury* 2011; 42:1198–204.
4. Fanelli G.C, Orcutt D.R, Edson C.J. The Multiple-Ligament Injured Knee: Evaluation, Treatment, and Results. *J Arthroscopic Related Surgery* 2005; 21(4):471-86.
5. Moore TM. Fracture--dislocation of the knee. *Clin Orthop Relat Res* 1981 ;(156):128-40.
6. Pelsner P.. Controversies in the management of tibial plateau fractures. *SAOJ* 2010; 75-82.
7. Durakbasa M.O, Ülku K, Ermis M.N. Irreducible open posterolateral knee dislocation due to medialmeniscus interposition. *Acta Orthop Traumatol Turc* 2011; 45(5):382-6.
8. Gardner M.J, Yacoubian S, Geller D. The incidence of soft tissue injury in operative tibial plateau fractures: a magnetic resonance imaging analysis of 103 patients. *J Orthop Trauma* 2005; 19:79–84.
9. Yacoubian S.V, Nevins R.T, Sallis J.G, Potter H.G, Lorich D.G. Impact of MRI on treatment plan and fracture classification of tibial plateau fractures. *J Orthop Trauma* 2002; 16:632–7.
10. Fox M.G. MR imaging of the meniscus: review, current trends, and clinical implications. *Magn Reson Imaging Clin N Am* 2007; 15:103–23.
11. Weigel D.P, Marsh J.L. High-energy fractures of the tibial plateau: knee function after longer follow-up. *J Bone Joint Surg Am* 2002; 84A:1541–51.

12. Shepherd L, Abdollahi K, Lee J, Vangsness C.T. The prevalence of soft tissue injuries in nonoperative tibial plateau fractures as determined by magnetic resonance imaging. *J Orthop Trauma* 2002; 16:628–31.
13. Wirbel RJ, Vrabac C, Pohlemann T, Hopp S. Inter- and Intraobserver Reliability for AO / ASIF and Moore Classification of Tibial Plateau Fractures – A Retrospective Study. *Ann Orthop Rheumatol* 2015; 3(2): 1048.
14. Aronson D, Singer R, Higgiris R. Skeletal traction for fractures of the femoral shaft in children. *J Bone Joint Surg* 1987; 69-A: 1435-8.
15. Porat S, Milgrom C, Nyska M. Femoral fracture treatment in head injured children: use of external fixation. *J Trauma* 1986; 26: 81-4.
16. Aronson J, Tursky E.A. External fixation of femur fractures in children. *J Pediatr Orthop* 1992; 12: 157-63.
17. Beaty J.H, Austin S.M, Warner W.C. Interlocking intramedullary nailing of femoral-shaft fractures in adolescents: preliminary results and complications. *J Pediatr Orthop* 1994; 14:178-83.
18. Mustonen A.O.T, Koivikko M.P, Lindahl J, Koskinen S.K. MRI of Acute Meniscal Injury Associated with Tibial Plateau Fractures: Prevalence, Type, and Location. *AJR* 2008; 191:1002–9.
19. Eranki V, Begg C, Wallace J. Outcomes of Operatively Treated Acute Knee Dislocations. *Open Orthopaedics J* 2010, 4, 22-30.
20. Stannard J.P, Lopez R, Volgas D. Soft tissue injury of the knee after tibial plateau fractures. *J Knee Surg* 2010; 23(4):187-92.
21. Gardner M.J, Yacoubian S, Geller D, Suk M, Mintz D, Potter H, et al. The incidence of soft tissue injury in operative tibial plateau fractures: a magnetic resonance imaging analysis of 103 patients. *J Orthop Trauma* 2005;19(2):79-8.
22. Shepherd L, Abdollahi K, Lee J, Vangsness C.T. The Prevalence of Soft Tissue Injuries in Nonoperative Tibial Plateau Fractures as Determined by Magnetic Resonance Imaging. *J Orthopaedic Trauma* 2002;16(9):628-31.
23. Vangsness J.r.C.T, Ghaderi B, Hohl M, Moore T.M. Arthroscopy of meniscal injuries with tibial plateau fractures. *Bone and Joint Surgery J Bone Joint Surg Br* 1994;76(3): 488-90.
24. Almekinders L, Logan T. Results following treatment of traumatic dislocations of the knee joint. *Clin Orthop Relat Res* 1992; 284:203-7.
25. Frassica F.J, Sim F.H, Staebeli J.W. Dislocation of the knee. *Clin Orthop Relat Res* 991; 263:200-5.
26. Harner C.D, Walirip R.L, Bennett C.H. Surgical management of knee dislocations. *J Bone Joint Surg Am* 2004; 86A:262-73.
27. Liow R.Y, Mc Nicholas M.J, Keating J.R. Ligament repair and reconstruction in traumatic dislocation of the knee. *J Bone Joint Surg Br* 2003; 85B:845-51.
28. Rios A, Villa A, Fahandezh H. Results after treatment of traumatic knee dislocations: a report on 26 cases. *J Trauma* 2003; 55:489-94.
29. Moigomery T, Savioe F, White J. Orthopedic management of knee dislocations: comparison of surgical reconstruction of surgical reconstruction and immobilization. *Am J Knee Surg* 1995; 8:97-103.
30. Green RN, Pullagura MK, Holland JP. Irreducible fracture-dislocation of the knee. *Acta Orthop Traumatol Turc* 2014;48(3):363-6.
31. Moore TM. Fracture-dislocation of the knee. *Clin Orthop Relat Res* 1981;156:128-40.