



Protective Effect of Crocin on Ovarian Ischemia-Reperfusion Injury in Rats

Masumeh Mohammadpour¹, Gholam Hossein Farjah*²

¹ Student Research Committee, Urmia University of Medical Sciences, Urmia, Iran

² Neurophysiology Research Center, Department of Anatomy, Faculty of Medicine, Urmia University of Medical Sciences, Urmia, Iran

*Corresponding authors: Gholam Hossein Farja, Address: Department of Anatomy, Faculty of Medicine, Urmia University of Medical Sciences, Urmia, Iran, Email: farjah.GH@umsu.ac.ir

Tel: +984432770698

Abstract

Background & Aims: Ischemia-reperfusion (I-R) injury of the ovary may lead to ovarian injury. In this study, we investigated the protective effect of the crocin on ovarian I-R injury.

Materials & Methods: Thirty-six male Sprague-Dawley rats were divided into 6 groups: sham surgery, ischemia, I-R, I-R+normal saline (NS), I-R+low dose crocin (20 mg/kg crocin), and I-R+ high dose crocin (80 mg/kg crocin). Neurological function, biochemical and histological evaluation was done 72 hours after ischemia.

Results: The plasma levels of malondialdehyde (MDA) and Total Antioxidative Capacity (TAC) in the ischemia, I-R, and I-R+ NS groups increased and decreased significantly compared to the crocin groups, respectively ($p<0.01$, $p<0.05$, respectively). Catalase activity in the high dose crocin group was higher than the ischemia, I-R, and I-R+ NS groups ($p<0.01$). The mean scores of edema, congestion, hemorrhage, and follicular degeneration were significantly lower than in the crocin groups than in the ischemia, I-R, and I-R+NS groups ($p<0.05$).

Conclusion: Findings suggest that crocin may protect ovary from ischemia-reperfusion injury.

Keywords: Crocin, Ischemia, Reperfusion, Ovary, Rat

Received 11 August 2020; accepted for publication 16 November 2020

Introduction

Ovarian torsion is the rotation of the ovary around the suspensory ligament containing the ovarian artery (1), and occurs more frequently in women of childbearing age (2). Ovarian torsion may severely reduce or cut off the blood flow to the ovary (ischemia) and ovarian detorsion (during emergency surgery)

causes blood flow (reperfusion). Previous studies showed that ischemia-reperfusion (I-R) injury causes oxidative stress and inflammation in a number of tissues, including the spinal cord (3), brain, heart, kidney, testis (4), renal graft (5), and ovary (6).

In addition to the development of surgical techniques (7), the administration of synthetic and

natural medicines with anti-inflammatory and anti-oxidant properties, including losartan (8), iloprost (9), sildenafil, and tadalafil (10) are used to reduce ovarian damage after I-R.

Saffron is effective in reducing I-R injury (11). Crocin is one of the effective components of saffron as a carotenoid (12). Numerous studies showed that crocin has anti-inflammatory (13), and antioxidant properties (14). It has a protective effect on hepatic (15), gastric (16), and cerebral I-R injury (17) and acts as a neuroprotective agent (18).

A previous study showed that crocin improves oocytes development during *in vitro* (19). To the best of our knowledge, although crocin has antioxidant and anti-inflammatory features, its effect on ovarian I-R injury has not yet been investigated. In the present study, we examined whether crocin administration can protect rat ovaries from I-R injury.

Materials and Methods

Experimental Design:

The animals (male rats, Sprague-Dawley, 200-240 g, n=36) were randomly divided into six groups: Sham surgery, ischemia, I-R, I-R + normal saline (NS), I-R + Low dose crocin (20 mg/kg crocin), and I-R + high dose crocin (80 mg/kg crocin). This study was approved by the ethical committee of Urmia University of Medical Sciences. The animals were kept under a 12-h light cycle (Ethical No: IR.UMSU.REC.1395.591).

Surgery Procedure:

Rats were anesthetized with ketamine-xylazine (90 and 10 mg/kg, respectively, i.p.), and anesthesia was maintained with continuous or repeated administration of it. Then, under sterile conditions, a longitudinal incision (2.5 cm) was performed in the median line of the lower abdomen.

In the sham surgery group (without induction of I-R injuries), the left ovary was observed, and then the abdominal wall was closed in 3-0 silk sutures.

The I-R procedure was performed as follows: left ovary was rotated 360° in a clockwise direction by the vascular clips and fixed on the abdominal wall with silk suture material (20). At the end of a 3-hour period of

torsion (ischemia), the vascular clips were removed, and a 3-hour period of detorsion (reperfusion) was continued (21).

Thirty minutes before the induction of ischemia, the animals in crocin and NS groups received a single dose of crocin (20 and 80 mg/kg; i.p., Sigma -Aldrich) and NS (1ml; i.p.), respectively.

The estrous stage of each rat was determined by a vaginal smear and cell types were examined under a microscope (staining Papanicolaou) (22).

Blood Sampling:

At the end of detorsion period, all the animals were anesthetized. The blood samples from each rat were obtained by a direct cardiac puncture, centrifuged at 1500 g for 15 min at +4 °C, and the plasma samples were stored at -80°C until the time of assay for plasma levels of malondialdehyde (MDA), Total Antioxidative Capacity (TAC), and catalase (23).

Biochemical Measurements:

In accordance with the kit guides, the plasma levels of catalase, MDA, TAC were performed (Zellbio Veltlingrweg 29, 89075 Ulm, Germany). Briefly, MDA of plasma was treated with the thiobarbituric, and the pink color was evaluated using spectrophotometer (532 nm). The level of TAC was determined based on the peroxide-peroxidase activity, and changes in the color from pink to yellow were measured using a spectrophotometer (450 nm). In addition, the level of catalase was determined by a spectrophotometer (240 nm) (23).

Histological Evaluation:

In the experimental groups, the left ovary was removed. After performing the tissue preparation steps (fixed in 10% formalin, embedded in paraffin, cut in 5 µm) the samples were stained with hematoxylin-eosin (H&E). All the sections were examined to determine the ovary tissue damage (interstitial edema, congestion or vascular dilation, hemorrhage, and degenerated follicles), and were ranked as follows 0: none; 1: less than 33%; 2: 33-66%; 3: >66%). The follicles that contained an oocyte with a pyknotic nucleus and shrunken ooplasm were considered to be degenerated follicles (22).

Statistical Analysis:

Statistical analysis was done by one-way ANOVA, and followed by Tukey's post hoc test. Tissue damage scores were analyzed by the Kruskal-Wallis, and followed by Mann-Whitney test. Data were expressed as means \pm standard error and statistical significance was defined as $p < 0.05$.

Results

All animals survived the test. In the macroscopic study, all ovaries (in the experimental groups) had a hemorrhagic appearance.

The plasma level of MDA increased significantly in ischemia, I-R, and I-R+ NS groups, compared to the crocin and sham groups ($p < 0.01$). This data shows that 20 and 80 mg/kg doses of crocin reduced the plasma level of MDA to 9.81 ± 1.41 , and 8.12 ± 0.94 , respectively. There was no significant difference between the crocin groups in plasma concentrations of MDA ($p > 0.05$) (Fig. 1).

Finding from the ischemia, I-R, and I-R+NS groups showed a significant decrease in plasma level of TAC, when compared with crocin groups ($p < 0.05$). In addition, plasma level of TAC increased significantly in crocin (80 mg) than in crocin (20 mg) ($p < 0.01$) (Fig. 2).

Catalase activity was significantly higher in the crocin (80 mg) group than in the ischemia, I-R, and I-R+NS groups ($p < 0.01$). The effect of a 20 mg/kg dose of crocin was not significantly increased in plasma level of catalase in comparison with the ischemia, I-R, and I-R+NS groups ($p > 0.05$) (Fig. 3).

The light microscopy showed a degree of edema, congestion, hemorrhage, and degenerated follicles in the experimental groups. In the sham surgery group, the ovaries had a histologically normal appearance without hemorrhage, and congestion (Fig. 4).

The mean scores of edema, congestion, and hemorrhage were significantly lower in the crocin groups than in the ischemia, I-R, and I-R+NS groups ($p < 0.01$). In addition, the mean scores of follicular degeneration were significantly lower in the crocin groups than in the ischemia, I-R, I-R+NS groups ($p < 0.05$). Besides, the mean score of follicular degeneration was significantly lower in the high crocin group than in the low crocin group ($p < 0.05$).

However, approximately 33%, 53%, and 62% of follicular??? were lost in ischemia, I-R, and I-R+NS groups, respectively. This amount was only 16% and 25% in high and low crocin groups, respectively (Table 1).

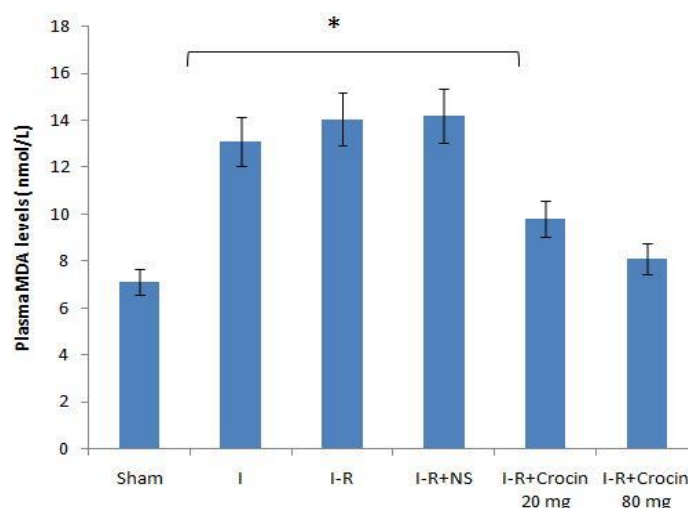


Fig. 1. The mean plasma level of Malondialdehyde (MDA) determined at 72 hours after ovarian ischemia reperfusion injury. * demonstrated a significant difference ischemia, I-R, and I-R+NS groups in comparison with crocin groups ($p < 0.01$).

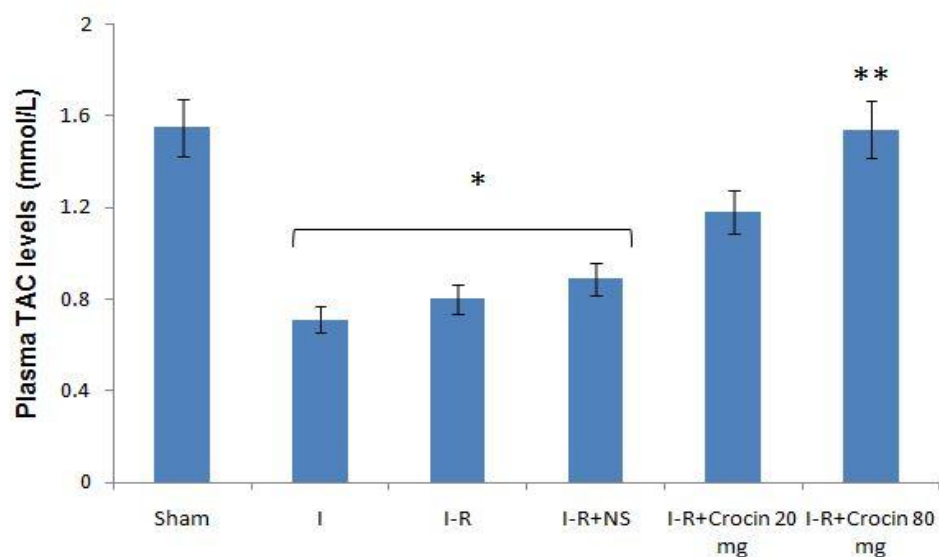


Fig. 2. The mean plasma level of Total Antioxidative Capacity (TAC) determined at 72 hours after ovarian ischemia reperfusion injury. * demonstrated a significant difference ischemia, I-R, and I-R+NS groups in comparison with crocin groups ($p < 0.05$). ** demonstrated a significant difference crocin (80 mg/kg) group in comparison with crocin (20 mg/kg) group ($p < 0.01$).

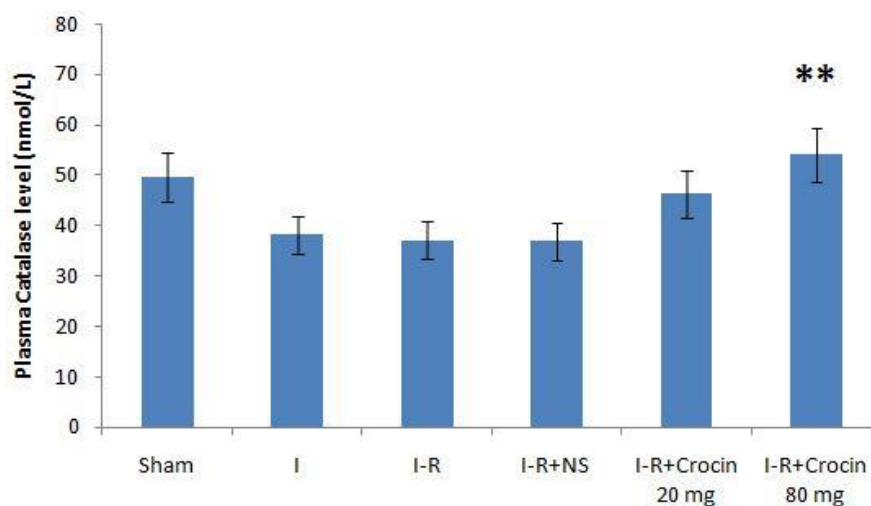


Fig. 3. The mean plasma level of Catalase determined at 72 hours after ovarian ischemia reperfusion injury. ** demonstrated a significant difference crocin (80 mg/kg) group in comparison with ischemia, I-R, and I-R+NS groups ($p < 0.05$).

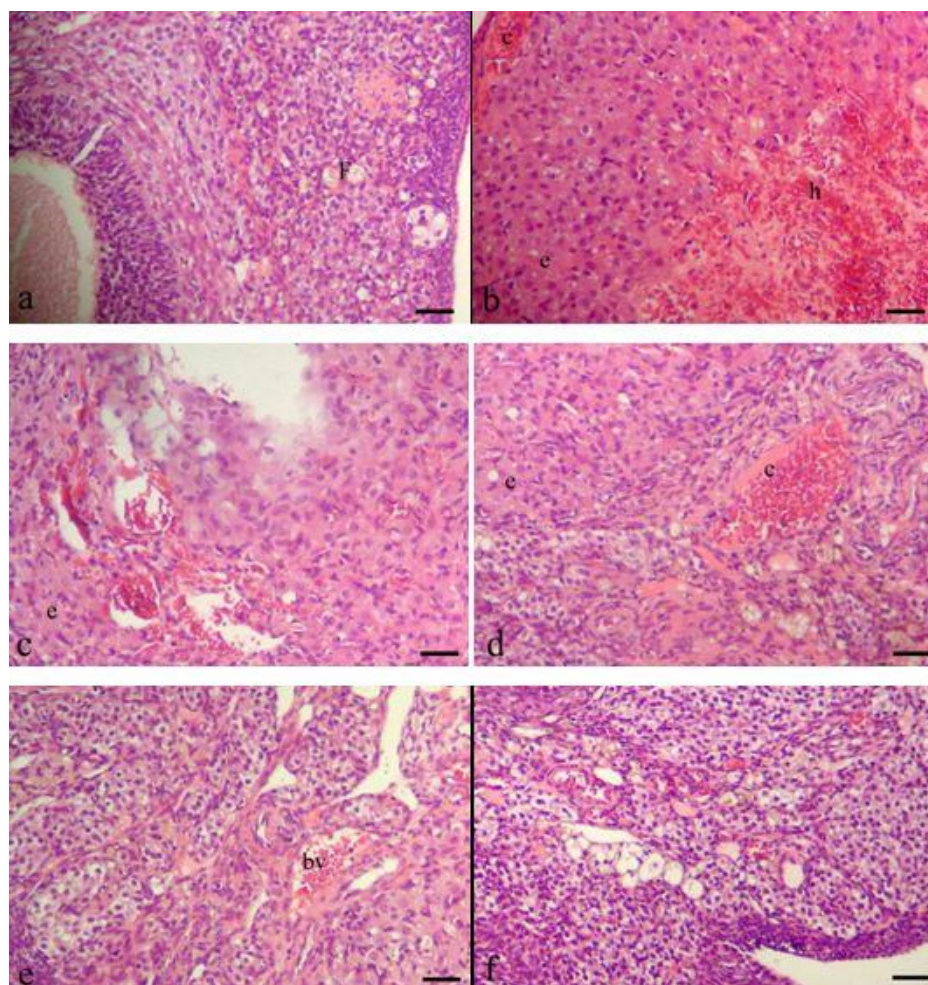


Fig. 4. Light microphotographs of ovary at 72 hours after ischemia reperfusion injury. sham surgery (a), ischemia (b), I-R (c), I-R+NS (d), I-R+Crocin 20 mg (e), I-R+Crocin 80 mg (f). f: follicles, C:congestion, e:edema, h:hemorrhage, fd:follicular degeneration, bv:blood vessel (H-E staining, Scale bar =100 μ m).

Table 1. Histopathological scores, 72 hours after ovarian ischemia reperfusion injury

Groups	Edema	Vascular Congestion	Hemorrhage	Follicular Degeneration
Sham Surgery	0.33 \pm 0.17	0.16 \pm 0.09	0.16 \pm 0.07	0.11 \pm 0.08
Ischemia	2.37 \pm 0.46	2.12 \pm 0.31	2.25 \pm 0.34	0.63 \pm 0.19
I-R	2.97 \pm 0.25	1.83 \pm 0.24	2.1 \pm 0.28	0.93 \pm 0.32
I-R+ NS	2.19 \pm 3.4	1.88 \pm 0.31	2.27 \pm 0.24	0.89 \pm 0.31
I-R+ Crocin (20 mg)	1.33 \pm 0.3*	1.24 \pm 0.16*	1.5 \pm 0.37*	0.25 \pm 0.11*
I-R+ Crocin (80 mg)	0.53 \pm 0.19*	1.1 \pm 0.15*	1.21 \pm 0.34*	0.16 \pm 0.07*, #

*Difference between crocin 80 mg group and crocin 20 mg group ($P < 0.05$).

*Difference between crocin groups and ischemia, I-R, I-R+NS groups ($P < 0.01$).

Discussion

Our results showed that crocin had a protective effect on ovarian I-R injury 72 h after ischemia. The present study is the first report describing the protective effect of crocin on I-R of ovary in rats.

Similar to the previous study (24), our results show that in the I-R groups, the biochemical analysis showed that TAC and CAT levels were significantly higher and MDA levels were significantly lower in crocin groups (especially in the crocin 80 mg group) compared to the I-R groups. Previous study showed that crocin plays a protective effect on gastric mucosal I-R injury (25). So, crocin decreased MDA, and increased the mRNA expression of superoxide dismutase (SOD) and glutathione peroxidase (Gpx) (25). In addition, our findings showed that MDA levels were higher in I-R groups compared to the ischemia group. In the reperfusion stage, free oxygen radicals react with lipids and lipid peroxides are formed (24). Sefidgar et al. (2019) showed that administration of crocin increased the plasma level of TAC in diabetic rats (26). On the other hand, the enzyme catalase has a great effect on tissue protection against reactive oxygen species (ROS) (27). It seems that antioxidant properties of crocin (28) may protect the ovaries from I-R injury by reducing free radicals.

Our findings revealed that crocin therapy (especially 80 mg) compared to NS protects ovarian tissue from I-R injury. The ovarian torsion blocks the ovarian vessels and prevents the return of venous blood, which in turn causes edema and internal hemorrhage (22). Reperfusion injury increased many factors including inflammation and neutrophil accumulation (29). The administration of crocin significantly decreased edema, hemorrhaging, vascular congestion, and follicular degeneration. A previous study observed that crocin can inhibit inflammation in the I-R injury (28).

We found that ischemia for 3 h led to histopathological changes in ovaries similar to the findings of Tunc et al. (2016) (24). Following long-term ischemia, the improper microvascular function is observed in the reperfusion stage (30). On the

reperfusion stage and after infiltrating neutrophils, reactive oxygen species (ROS) are produced in large quantities (31). However, crocin causes ROS inhibition. So that the ROS block is considered a therapeutic approach (32). In addition, the previous study showed that ROS plays a key role in myocardial healing by clearance of dead cells (31).

In the present study, the mean number of degenerated follicles in the crocin groups was lower than the ischemia, I-R, I-R+NS groups. A previous study showed that honokiol, which has antioxidant and anti-inflammatory effects, reduces cell degeneration (24). Administration of crocin can maintain the normal shape and the microscopic architecture of testicular tissue in diabetic rats (26). Crocin can also be considered as an anti-aging agent by inhibiting ROS production and advanced glycation end product expression (33). Thus, it was suggested that antioxidant and anti-inflammatory properties of crocin decrease I-R injury, and increase the survival of follicles in ovarian tissue.

One of the limitations of this study was short-term. Since it is possible to increase the damage of tissue by increasing the time of reperfusion, we believe that it is necessary to study the long-term effect of crocin on the I-R injury of ovarian.

Our findings are in agreement with a previous study that crocin with a dose of 80 mg/kg has more protective effect than a dose of 20 mg/kg (18). So that the mean scores of edema, congestion, and hemorrhage were significantly lower in the crocin (80 mg/kg) group than in the crocin (20 mg/kg) group. Crocin may attenuate cellular apoptosis by reducing oxidative stress and inflammation (18), and reduce brain damage after ischemia (34).

Conclusion

According to the histological and biochemical results of this study, it is suggested that crocin may have a protective effect on ovarian ischemia-reperfusion injuries. While the anti-inflammatory and antioxidant activity of crocin is known, the effect of crocin on ovarian tissue may be multifactorial. Therefore, further

studies are needed to investigate the molecular mechanism of crocin on I-R of the ovary.

Acknowledgments

This research was supported by a grant from Urmia University of Medical Sciences in Urmia, Iran.

References

- Gomes MM, Cavalcanti LS, Reis RL, Silva EJDCE, Dutra JB, de Melo-Leite AF. Twist and shout: magnetic resonance imaging findings in ovarian torsion. *Radiol Bras* 2019; 52(6):397-402.
- Feng JL, Zheng J, Lei T, Xu YJ, Pang H, Xie HN. Comparison of ovarian torsion between pregnant and non-pregnant women at reproductive ages: sonographic and pathological findings. *Quant Imaging Med Surg* 2020; 10(1):137-47.
- Mohammad Pour M, Farjah GH, Karimipour M, Pourheidari M, Khadam Ansari MH. Protective effect of lutein on spinal cord ischemia-reperfusion injury in rats. *Iranian J Basic Med Sci* 2019; 22(4):412-17.
- Minutoli L, Puzzolo D, Rinaldi M, Irrera N, Marini H, Arcoraci V, et al. ROS-Mediated NLRP3 inflammasome activation in brain, heart, kidney, and testis Ischemia/Reperfusion Injury. *Oxid Med Cell Longev* 2016;2016:2183026.
- Zhao H, Alam A, Soo AP, George AJT, Ma D. Ischemia-Reperfusion injury reduces long term renal graft survival: mechanism and beyond. *EBioMedicine* 2018;28:31-42.
- Tokgoz VY, Sipahi M, Keskin O, Guvendi GF, Takir S. Protective effects of vitamin D on ischemia-reperfusion injury of the ovary in a rat model. *Iran J Basic Med Sci* 2018;21(6):593-9.
- Balasubramaniam D, Duraisamy KY, Ezhilmani M. Laparoscopic detorsion and fertility preservation in twisted ischemic adnexa – A single – center prospective study. *Gynecol Minim Invasive Ther* 2020; 9 (1):24-8.
- Hortu I, Ilgen O, Sahin C, Akdemir A, Yigitturk G, Erbas O. Losartan ameliorates ovarian ischaemia/reperfusion injury in rats: an experimental study. *J Obstet Gynaecol* 2020; 1-7.
- Karaçor T, Dogan Z, Elibol E, Bulbul M, Nacar MC. Effects of iloprost on experimental ischemia and reperfusion injury in rat ovary. *Biotec Histochem* 2020; 95(3): 373-80.
- Sakin O, Anđin AD, Akalin EE, Ciman MS, Basak K, Kaptanagasi AO. Comparison of the protective effects of sildenafil, vardenafil and tadalafil treatments in ischemia-reperfusion injury in rat ovary. *Ginekol Pol* 2019; 90 (2):513-9.
- Farjah GH, Salehi S, Ansari MH, Pourheidari B. Protective effect of *Crocus sativus* L. (saffron) extract on spinal cord ischemia-reperfusion injury in rats. *Iran J Basic Med Sci* 2017; 20(3):334-37.
- Oncchiai T, soeda SH, Ohno s, tanaka h, shoyama y, shimeno h. crocin prevents the death of PC-12 cells through sphingomyelinase-ceramide signaling by increasing glutathione synthesis. *Neurochem* 2004; 44:321-30.
- Liu W, Sun Y, Cheng Z, Guo Y, Liu P, Wen Y. Crocin exerts anti-inflammatory and anti-arthritis effects on type II collagen-induced arthritis in rats. *Pharm Biol* 2018;56(1):209-16.
- Wang C, Cai X, Hu W, Li Z, Kong F, chen X, et al. Investigation of the neuroprotective effects of crocin via antioxidant activities in HT22 cells and in mice with Alzheimer's disease. *Int J Mol Med* 2019;43(2):956-66.
- Akbari G, Mard SA, Dianat M. Effect of crocin on cardiac antioxidants, and hemodynamic parameters after injuries induced by hepatic ischemia-reperfusion in rats. *Iran J Basic Med Sci* 2019; 22(3):277-81.
- Mard SA, Azad SM, Ahangarpour A. Protective effect of crocin on gastric mucosal lesions induced by ischemia-reperfusion injury in rats. *Iran J Pharm Res* 2016; 15 (Suppl):93-9.
- Zhang Y, Geng J, Hong Y, Jiao L, Li S, Sun R, et al. Orally administered crocin protects against cerebral ischemia/reperfusion injury through the metabolic transformation of crocin by gut microbiota. *Front Pharmacol* 2019; 10:440.
- Mozaffari S, Ramezany Yasuj S, Motaghinejad M, Motevalian M, Kheiri R. Crocin acting as a neuroprotective agent against methamphetamine-induced neurodegeneration via CREB-BDNF signaling pathway. *Iran J Pharm Res* 2019; 18(2):745-58.

19. Mokhber Maleki E, Eimani H, Bigdeli MR, Golkar Narenji A, Abedi R. Effects of Crocin Supplementation during In Vitro Maturation of Mouse Oocytes on Glutathione Synthesis and Cytoplasmic Maturation. *Int J Fertil Steril* 2016;10(1):53–61.
20. Akdemir A, Erbas O, Gode F, Ergenoglu M, Yenieli O, Oltulu F. Protective effect of oxytocin on ovarian ischemia-reperfusion injury in rats. *Peptides* 2014; 55:126-30.
21. Oral A, Odabasoglu F, Halici Z, Keles ON, Unal B, Coskun AK, et al. Protective effects of montelukast on ischemia-reperfusion injury in rat ovaries subjected to torsion and detorsion: biochemical and histopathologic evaluation. *Fertil Steril* 2011; 95(4):1360-6.
22. Yildirim N, Yigitturk G, Yildirim AGS, Akdemir A, Ilgen O, Yenieli O, et al. Octretide protects ovary against ischemia-reperfusion injury in rats: evaluation of histological and biochemical parameters. *J Obstetrics Gynaecology Res* 2015; 41(10):1591-7.
23. Karimipour M, Farjah GH, Molazadeh F, Ansari M, Pourheidar B. Protective effect of contralateral, ipsilateral, and bilateral remote ischemic preconditioning on spinal cord ischemia reperfusion injury in rats. *Turk Neurosurg* 2019; 29(6):933-9.
24. Tunc Sy, Agacayak E, Goruk NY, Icen MS, Turgut A, Alablik U, et al. Protective effects of honokiol on ischemia/reperfusion injury of rat ovary: an experimental study. *Drug Des Devel Ther* 2016; 10:1077-83.
25. Mard SA, Azad SM, Ahangarpour A. Protective effect of crocin on gastric mucosal lesions induced by ischemia-reperfusion injury in rats. *Iran J Pharm Res* 2016; 15:93-9.
26. Sefidgar SM, Ahmadi-Hamedani M, Jebelli Javan A, Narenji Sani R, Javaheri Vayghan A. Effect of crocin on biochemical parameters, oxidative/antioxidative profiles, sperm characteristics and testicular histopathology in streptozotocin-induced diabetic rats. *Avicenna J Phytomed* 2019; 9(4):347-61.
27. Wali AF, Rashid S, Rashid SM, Ansari MA, Khan MR, Haq N, et al. Naringenin regulates doxorubicin-induced liver dysfunction: impact on oxidative stress and inflammation. *Plants (Basel)* 2020; 9(4): E550.
28. Mohamadi Yarijani Z, Pourmotabbed A, Pourmotabbed T, Najafi H. Crocin has anti-inflammatory and protective effects in ischemia-reperfusion induced renal injuries. *Iran J Basic Med Sci* 2017; 20:753-9.
29. Zhang P, Yue K, Liu X, Yan X, Yang Z, Duan J, et al. Endothelial notch activation promotes neutrophil transmigration via downregulating endomucin to aggravate hepatic ischemia/reperfusion injury. *Sci China Life Sci* 2020; 63(3):375-87.
30. Spears JR. Reperfusion microvascular ischemia after prolonged coronary occlusion. *Hypoxia (Auckl)* 2019; 7:65-79.
31. Carbone F, Bonaventura A, Montecucco F. Neutrophil-related oxidants drive heart and brain remodeling after ischemia/reperfusion injury. *Front Physiol* 2020; 10:1587.
32. Nie Z, Deng S, Zhang L, Chen S, Lu Q, Peng H. Crocin protects against dexamethasone-induced osteoblast apoptosis by inhibiting the ROS/Ca²⁺-mediated mitochondrial pathway. *Mol Med Rep* 2019; 20(1):401-8.
33. Heidary S, Mehri S, Shariaty V, Hosseinzadeh H. Preventive effects of crocin on neuronal damages induced by D-galactose through AGEs and oxidative stress in human neuroblastoma cells (SH-SY5Y). *J Pharmacopuncture* 2018; 21(1):18-25.
34. Huang A, Jia L. Crocin enhances hypothermia therapy in hypoxic ischemia-induced brain injury in mice. *Acta Neurol Belg* 2019:1-8.