



Challenging the existent dogma - synthetic mesh placement in enterostomy closure

Satyam Soni¹, Dileep Thakur², Reena Kothari³, Amrendra Verma^{4*}, Uday Somashekar⁵, Dhananjay Sharma⁶

¹ MBBS, MS. Department of General Surgery, Netaji Subhash Chandra Bose (NSCB) Medical College, Garha, Jabalpur, Madhya Pradesh, India

² MBBS, MS. Department of General Surgery, Netaji Subhash Chandra Bose (NSCB) Medical College, Garha, Jabalpur, Madhya Pradesh, India

³ MBBS, MS. MS Department of General Surgery, Netaji Subhash Chandra Bose (NSCB) Medical College, Garha, Jabalpur, Madhya Pradesh, India

⁴ MBBS, MS, DNB. MS Department of General Surgery, Netaji Subhash Chandra Bose (NSCB) Medical College, Garha, Jabalpur, Madhya Pradesh, India

⁵ MBBS, MS, DNB. MS Department of General Surgery, Netaji Subhash Chandra Bose (NSCB) Medical College, Garha, Jabalpur, Madhya Pradesh, India

⁶ MBBS, MS, PhD, DSc, FRCS. MS Department of General Surgery, Netaji Subhash Chandra Bose (NSCB) Medical College, Garha, Jabalpur, Madhya Pradesh, India

***Corresponding authors:** Amrendra Verma, **Address:** Department of General Surgery, Netaji Subhash Chandra Bose (NSCB) Medical College, Garha, Jabalpur, Madhya Pradesh, India, **E-Mail:** verma.amrendra4@gmail.com, **Tel:** +917612370951

Abstract

Background & Aims: Enterostomy reversal and fascial defect cause weakness in the abdominal wall and may lead to formation of incisional hernia. Literature says that placement of synthetic mesh in dirty/contaminated wound causes high chances of surgical site infection (SSI) and mesh related complications. This dogma is now challenged. Present study was conducted to evaluate outcome of the placement of synthetic non-absorbable mesh after enterostomy closure in terms of SSI and incisional hernia.

Materials & Methods: This prospective case-control study was conducted in the department of General surgery Netaji Subhash Chandra Bose (NSCB) medical college, Jabalpur, between 1st December 2018 to 30th September 2020. All patients of age >18 years with ileostomy/colostomy undergoing enterostomy reversal were included. Outcomes noted for wound infection/dehiscence, mesh related complications, its removal, and development of incisional hernia.

Results: Total 60 patients were included in this study. Out of which, 30 (23 loop ileostomy, 5 double barrel ileostomy, and 2 colostomy) were taken as the case; where polypropylene mesh was placed (9 sublay and 21 onlay). 30 others (28 loop ileostomy, 1 double barrel ileostomy, and 1 colostomy) were taken as control where mesh was not placed after stoma closure. SSI was significantly lower in mesh placed group than non-mesh placed group (16.6% vs. 40%; P=0.019). Use of mesh was associated with slightly better outcomes but not significant in terms of rate of wound dehiscence (3.3% vs. 6.7%; Z=0.59; P=0.554) and incisional hernia (0 vs 6.7%; p= 0.492) in mesh and non-mesh groups, respectively. Mesh removal for chronic infection was not required in any case.

Conclusion: Placement of permanent synthetic polypropylene mesh at the site of enterostomy closure for prevention of incisional hernia can be done safely without fear of having increased risk of SSI and need of mesh removal.

Keywords: Synthetic mesh, stoma, infection, incisional hernia, wound dehiscence

Received 25 February 2022; accepted for publication 15 May 2022

Introduction

Incisional hernia at previous stoma site is a commonly seen delayed morbidity after its taken down causing patient to undergo hernioplasty and added further morbidity. A stoma site is basically a hernia with a full-thickness defect of the abdominal wall. Previous studies have shown a high rate of hernia formation at stoma sites in up to 30% cases (1), so it should be expected that simple closure of defect is associated with a high rate of incisional hernia formation.

The stoma site hernia repair may also have high risk of infection. Mesh reinforcement with a polypropylene mesh has not gain much culture despite this high rate of incisional hernia, because mesh placement in contaminated field is associated with increased rate of surgical site infection (SSI) (2). Recently increased level of safety with permanent mesh placement has shown in contaminated and dirty wounds too (3-6).

One study reported hernia rate of 34% and 37% at stoma and midline incision site, respectively (7-9). However clinical examination and ultrasonographic imaging showed a 32% incidence of stoma site hernia and 58% incidence of midline hernia in the same group of patients (10). Another study shows that 32.4% of patients of stoma reversal developed stoma site hernia, having obesity as an independent risk factor (11). As in recently done prospective randomized control trials with onlay polypropylene mesh reinforcement after colorectal surgery for midline incisional hernia,

prevention have shown decreased incidence of hernia with similar rates of SSI (5-6). Also prophylactic abdominal wall reinforcement after emergency laparotomy in contaminated wound shows decreased chances of hernia occurrence with similar rates of SSI (17.9 v 26.3%) (12); hence using large pore polypropylene mesh placements during stoma closure may provide a safe method of reducing development of incisional hernias.

Materials & Methods

This prospective comparative study was conducted in the department of General surgery NSCB medical college, Jabalpur, between 1st December 2018 to 30th September 2020 to assess the incidence of incisional hernia at stoma closure site between prophylactic polypropylene mesh placement v/s conventional method of closure and frequency of surgical site infection. All persons over 18 years of age were included. All surgical procedures were done with standards of stoma closure and resection anastomosis of ileal/colon loop except four patients of the case group where midline exploration was done and wound closed and reinforced with polypropylene mesh (pore size > 75 μ m) either by sublay or by onlay manner with suction drain. (Figure 1,2).

The operative wound was classified as 'contaminated' or 'dirty' as of the Centers for Disease Control and Prevention (CDC) criteria (13).

Fig 1

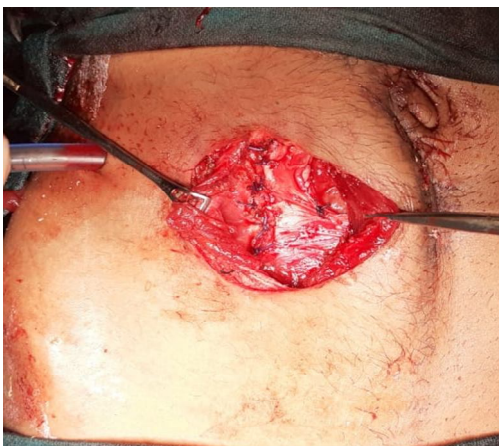

Fig2

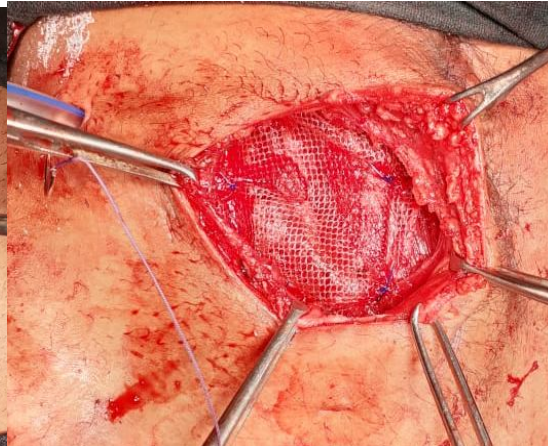


Fig 1 and 2: Sublay polypropylene mesh placement along with suction drain in ileostomy closure.

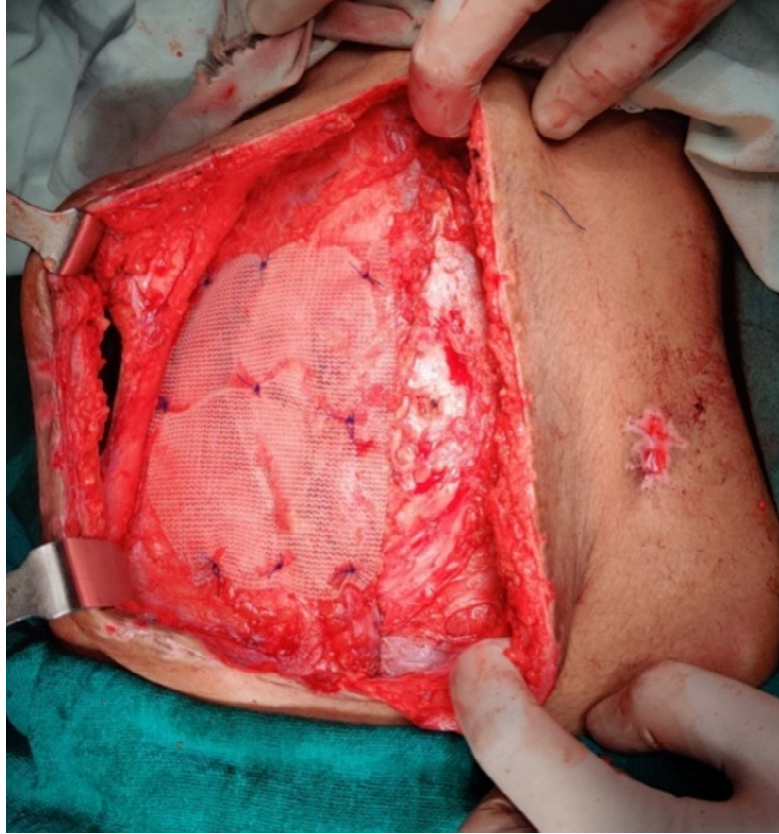

Fig 3: Mesh placement in midline during midline exploration.

Patients were managed postoperatively and allowed orally, if abdominal drain was placed then removed when output was < 30 ml serous in 24hrs. Suction drain was removed on output < 20 ml serous fluid/day. All the patients were examined on 1st postoperative day (POD), 3rd POD, 7th POD, 6th week, 3rd month and 6th month for SSI and incisional hernia formation.

In this study, outcome of patients undergone polypropylene mesh reinforcement following stoma closure was measured and compared it in the patients with conventional stoma closure without mesh reinforcement. The adequate required sample size was estimated using the following formula: $n = z^2pq/d^2$, where n = sample size, $z = 1.96$ (considering 0.05 alpha, 95% confidence limits and 80% beta), p = assumed probability of occurrence or concordance of results, $q = 1 - p$, and d = marginal error (precision).

Data collected in predesigned form and noted in MS

Excel worksheet which was further exported to SPSS version 20 for statistical analysis. All the categorical variables were tabulated in frequency and percentage and continuous variables were summarized in mean±SD. The Chi-square test was used to compare the contingency in 2×2 tables and Z test was applied to compare two independent proportions. The Student's *t* test was also used to compare significance between two independent means.

Results

During this study period, total 86 Ileostomy/colostomy closure were performed. Out of which 60 patients analysed after follow up, in which 30 were taken as case; where polypropylene mesh was placed (9 sublay and 21 onlay) and 30 were taken as control where mesh was not placed after stoma closure. Patient selection was random and as per [chart 1](#).

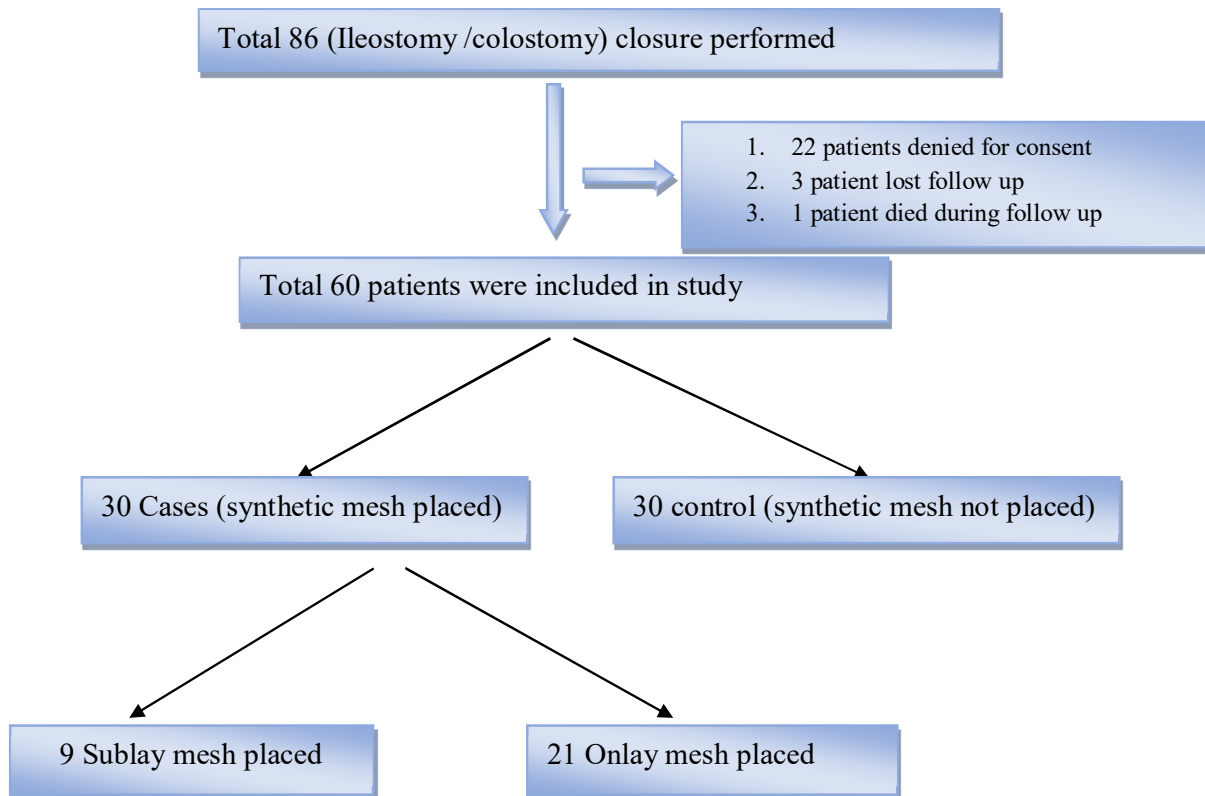


Chart 1. Patient selection chart

Demographics of the included patients was shown in [table 1](#).

Table 1. Demographics of included patients

Demographics	Case group n=30(%) (where synthetic mesh was placed)	Control group n=30(%) (where synthetic mesh was not placed)	P value
1. Age, mean (SD)	31.33 (11.9)	28.9 (8.9)	t=0.90; p=0.374
2. Sex			Chi square=0.80; P=0.371
males	21 (70)	24 (80)	
females	9 (30)	6 (20)	
3. Type of ostomy closure done			Chi square = 3.49; P=0.175
Loop ileostomy	23 (76.6)	28 (93.3)	
Double barrel ileostomy	5 (16.6)	1 (3.33)	
Colostomy	2 (6.66)	1 (3.33)	
4. Surgical site infection			
On 3 rd POD	2 (6.7)	11 (36.7)	Z=282; P=0.005
On 7 th POD	2 (6.7)	12 (40)	Z=3.05; P=0.0023
On 6 th Week	1 (3.3)	0	Z=1.01; P=0.313
5. Wound dehiscence	1 (3.3)	2(6.7)	Z=0.59; P=0.554
6. Stoma site incisional hernia(in 6 month follow up)	0	2(6.7)	P=0.492

Our study shows that 2 patients (6.7%) of the case group had SSI on 3rd POD, 2 (6.7%) on 7th POD, and 1 (3.3%) on the 6th week, while 11 patients (36.7%) of the control group showed SSI on 3rd POD and 12 (40%) on 7th POD. Here, p value is 0.019, showing that SSI was significantly higher in non-mesh group. Wound infection was managed by drainage of collection at the suture site. All these wounds healed by secondary intention. None of the patients require mesh removal during the entire study period. Wound infection was managed by dressings and antibiotics; only 3 out of 60 required secondary suturing of skin.

There is only 1 patient (3.3%) of the case group that had wound dehiscence while 2 (6.7%) of the control group had wound dehiscence; Mesh removal was not required and this difference was insignificant ($Z = 0.59$; $p=0.554$).

2 patients (6.7%) of control group developed stoma site incisional hernia during 6 months follows up, while none of the mesh placed patients developed stoma site incisional hernia (Chi square = 2.07; $P = 0.492$). During our follow-up, we found that 3 of the cases and 3 of the control group, i.e., 6/60 or 10% of the patients developed midline incisional hernia. None of these patients had a midline mesh placement in the study group. (Figure 4,5).

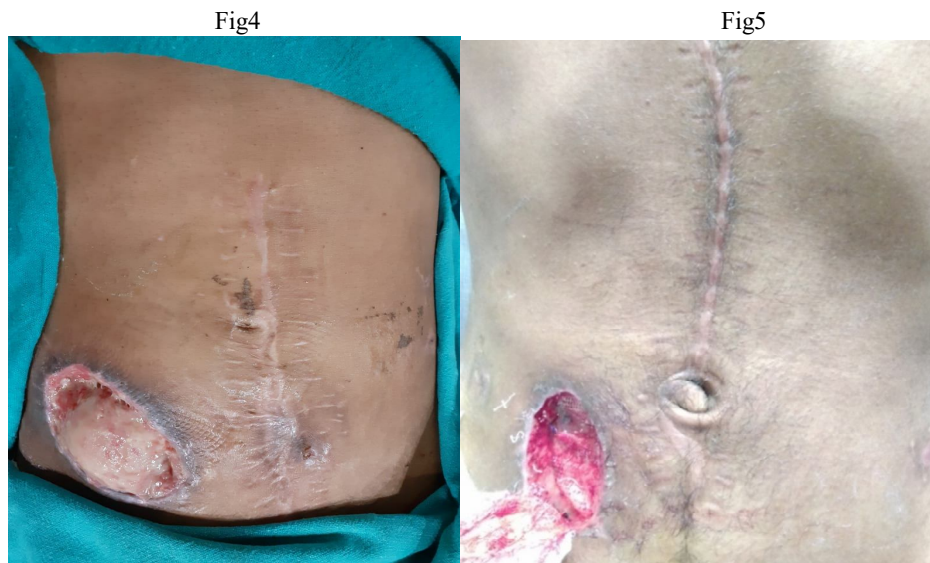


Fig 4 and 5. Wound dehiscence in stoma closure without and with mesh placement, respectively.

Discussion

Conventionally, it was thought that placement of a foreign part in body, i.e., non-absorbable polypropylene mesh, should be avoided at the site stoma closure due to fear of surgical site infection (14-15). Biological mesh reinforcement was preferred where synthetic mesh supposed to be contraindicated as in contaminated field (16), but recent studies on use of biological mesh in contaminated wound has not proven superior to permanent synthetic mesh in resisting infection (17-19), so they also may require second surgery for incisional hernia with polypropylene mesh.

When placing prosthetic mesh in a contaminated wound, most surgeons have fear of complications like fistula formation, need of mesh removal or need of prolonged antibiotic treatment (20). With improved mesh technology and surgical techniques, recent studies show the reduced incidence of stoma site hernias without increasing wound complication rates (21-24).

In the last couple of years, studies have shown that there is no increased risk of mesh-related complications or surgical site infection in contaminated surgeries, and non-absorbable synthetic mesh can be safely placed in parastomal hernia repair and stoma site reversal; there is

also no significant difference seen in SSI rate (25-28). Furthermore, non-absorbable synthetic meshes can be used safely in the settings of elective incisional hernia repairs where colorectal resection is being performed parastomal hernia repair and used for strangulated hernias where resection of non-viable intestine is required (29-36).

Study by Argudo et al. on onlay partially absorbable mesh placements for prophylactic abdominal wall reinforcement after emergency laparotomy, even in the setting of intra-abdominal sepsis shows decreased chances of hernia occurrence while maintaining similar rates of SSI (17.9 v 26.3%) (12). similarly, Two, recent

prospective randomized control trials in which onlay macroporous polypropylene mesh reinforcement after colorectal surgery for midline incisional hernia prevention show decreased hernia rate with similar rates of SSI between mesh and non-mesh groups (5, 6). No suitable explanation for this result can be thought of but this finding found similar results to meta-analysis done by Jeremy A. Warren in which incidence of superficial SSI was less with mesh groups than non-mesh group (8 vs 16.4%; $P = 0.039$) and a midline incisional hernia found in 45% of the mesh group vs. 4.5% in the non-mesh group (37).

Table 2. Comparisons between studies done on prophylactic mesh placement in clean contaminated/contaminated wound

S.no.	Study	Year	SSI in mesh group	SSI in without mesh group	Incisional hernia without mesh	Incisional hernia with mesh	P value (incisional hernia)	P value (SSI)
1	Maggiore, et al. (38)	2015	7%	2%	19%	3%	0.043	0.238
2	Jeremy A. Warren (37)	January 2008 to June 2015	8%	16.40%	17.20%	1%	<0.001	0.039
3	David Shi Hao Liu et al. (39)	January 2007 to December 2011	4.30%	2.80%	36.10%	6.40%	0.002	0.479
4	Argudo, et al.	2011 to 2014	17.90%	26.30%	33.30%	5.90%	0.001	0.13
5	ACS-NSQIP (Benlice C, et al. (40))	2005 To 2010	7.30%	10.50%	-	-	-	0.14
6	García-UreñaMÁ (41)	2015	18.90%	33.30%	31.50%	11.30%	0.011	0.12
7	In this study	December 2018 to September 2020	16.6%	40%	6.67%	nil	0.492	0.019

We placed suction drain to create negative pressure which promotes healing and decrease chances of surgical site infection rate; negative-pressure wound therapy is found to be a good option to prevent SSI (42).

In a previous study on placement of synthetic polypropylene mesh in strangulated hernia (inguinal, ventral or femoral) repair in emergency settings also shows promising results, where we can safely use synthetic mesh without increased risk of SSI or mesh being contaminated (43).

Our results show that the use of a polypropylene mesh in the contaminated wound of ileostomy or colostomy closure with suction drain is associated with acceptable morbidity and also decreased wound infection rate. It can be considered safe, as the wound infection could be managed in all our cases with conservative management and in none of the cases a mesh removal was required. We did not encounter any incident of anastomosis leak. If such a leak occurs, treatment would be based on the principles of managing any enterocutaneous fistula. Preventing a patient from

having stoma closure site incisional hernia, co morbidities associated with it, and resurgical intervention can give a better quality of life and decrease burden of disease. This operation could be done safely in a single sitting with synthetic mesh placement without having fear of mesh being contaminated and increased SSI. Our results suggest that the use of macroporous polypropylene mesh for reinforcement of stoma closure site is effective, safe, with acceptable morbidity, and with good short-term results. If not used routinely for all patients, it can be safely used in those patients where closure is under tension or who are at high risk of developing incisional hernia. However larger study group with randomization and longer follow-up is required.

Conflict of interest

The authors have no conflict of interest in this study.

References

- Schuster, Singh J, Safadi BY, Wren SM. The use of acellular dermal matrix for contaminated abdominal wall defect; wound status predict success. *Am J Surg* 2006;192(5):594-7
- Olsen MA, Nickel KB, Wallace AE, Mines D, Fraser VJ, Warren DK. Stratification of surgical site infection by operative factors and comparison of infection rates after hernia repair. *Infect Control Hosp Epidemiol* 2015;36(3):329-35
- Carbonell AM, Criss CN, Cobb WS, et al. Outcomes of synthetic mesh in contaminated ventral hernia repairs. *J Am Coll Surg* 2013;217:991-8.
- Fischer JP, Basta MN, Mirzabeigi MN, Kovach SJ. A comparison of outcomes and cost in VHWG grade II hernias between Rives-Stoppa synthetic mesh hernia repair versus underlay biologic mesh repair. *Hernia* 2014;18:781-9.
- García-Ureña MÁ, López-Monclús J, Hernando LAB, et al. Randomized controlled trial of the use of a large-pore polypropylene mesh to prevent incisional hernia in colorectal surgery. *Ann Surg* 2015;261:876-81.
- Caro-Tarrago A, Olona Casas C, Jimenez Salido A, et al. Prevention of incisional hernia in midline laparotomy with an onlay mesh: a randomized clinical trial. *World J Surg* 2014;38:2223-30.
- Saeed ZM, Lloyd-Evans J, Reid TD, et al. CT evaluation for “quiescent” herniation following closure of diverting loop ileostomy. *Colorectal Dis* 2012;14:1528-30.
- Bhangu A, Fletcher L, Kingdon S, et al. A clinical and radiological assessment of incisional hernias following closure of temporary stomas. *Surgeon* 2012;10:321-5.
- Cingi A, Cakir T, Sever A, Aktan AO. Enterostomy site hernias: a clinical and computerized tomographic evaluation. *Dis Colon Rectum* 2006;49:1559-63.
- Cingi A, Solmaz A, Attaallah W, et al. Enterostomy closure site hernias: a clinical and ultrasonographic evaluation. *Hernia* 2008;12:401-5.
- Schreinemacher MHF, Vijgen GHEJ, Dagnelie PC, et al. Incisional hernias in temporary stoma wounds: a cohort study. *Arch Surg* 2011;146:94-9.
- Argudo N, Pereira JA, Sancho JJ, et al. Prophylactic synthetic mesh can be safely used to close emergency laparotomies, even in peritonitis. *Surgery* 2014;156:1238-44.
- https://www.cdc.gov/nhsn/pdfs/pscma_nual/9pscs_sicurrent.pdf. Surgical Site Infection (SSI) Event. Accessed 31 Dec 2017
- Ferzoco SJ. A systematic review of outcomes following repair of complex ventral incisional hernias with biologic mesh. *Int Surg* 2013;98(4):399-408.
- Rosen MJ, Bauer JJ, Harmaty M et al. Multicenter, prospective, longitudinal study of the recurrence, surgical site infection, and quality of life after contaminated ventral hernia repair using biosynthetic absorbable mesh: the COBRA study. *Ann Surg* 2017;265(1):205-11.
- Novitsky YW. Biology of biological meshes used in hernia repair. *Surg Clin North Am* 2013;93(5):1211-5
- Alvarez JA, Baldonado RF, Bear IG, Solis JA, Alvarez P, Jorge JI. Incarcerated groin hernias in adults: presentation and outcome. *Hernia* 2004;8(2):121-26.
- López-Cano M, Quiles MT, Pereira JA, Armengol-Carrasco M, ArbósVía MA. Complex abdominal wall hernia repair in contaminated surgical fields: factors affecting the choice of prosthesis. *Am Surg* 2017;83(6):583-90.

19. Mariette C, Wind P, MicelliLupinacci R et al. Practice patterns in complex ventral hernia repair and place of biological grafts: a national survey among French digestive academic surgeons. *J Visc Surg* 2014;151(1):9–16.
20. Herbert GS, Tausch TJ, Carter PL. Prophylactic mesh to prevent incisional hernia: a note of caution. *Am J Surg* 2009;197:595–8 discussion 598.
21. Curro G, Centorrino T, Musolino C et al. Incisional hernia prophylaxis in morbidly obese patients undergoing biliopancreatic diversion. *Obes Surg* 2011;21:1559–63.
22. Strzelczyk JM, Szymanski D, Nowicki ME et al. Randomized clinical trial of postoperative hernia prophylaxis in open bariatric surgery. *Br J Surg* 2006;93:1347–50.
23. Kelly ME, Behrman SW. The safety and efficacy of prosthetic hernia repair in clean-contaminated and contaminated wounds. *Am Surg* 2002;68:524–528 discussion 528–9.
24. Birolini C, Utiyama EM, Rodrigues AJ et al. Elective colonic operation and prosthetic repair of incisional hernia: does contamination contraindicate abdominal wall prosthesis use? *J Am Coll Surg* 2000;191:366–72.
25. S.R. Steele et al. Is parastomal hernia repair with polypropylene mesh safe? *Am J Surg* 2003;185:436–40. doi:10.1016/S0002-9610(03)00040-0
26. JB Cornille, S Pathak, et al. Prophylactic mesh use during primary stomaformation to prevent parastomal hernia. *Ann R Coll Surg Engl* 2017; 99: 2–11. doi 10.1308/rcsann.2016.0186
27. Warren JA ,Beffa LR , Carbonell AM , et al. Prophylactic placement of permanent synthetic mesh at the time of ostomy closure prevents formation of incisional hernias. *Surgery* 2018;163:839–46
28. L. C. L. van den Hil, S. van Steensel, et al. Prophylactic mesh placement to avoid incisional hernias after stoma reversal: a systematic review and meta-analysis. *Hernia*. 2019; 23(4): 733–41.
29. Nieuwenhuizen J, van Ramshorst GH, ten Brinke JG et al. The use of mesh in acute hernia: frequency and outcome in 99 cases. *Hernia* 2011;15(3):297–300
30. Zafar H, Zaidi M, Qadir I, Memon AA. Emergency incisional hernia repair: a difficult problem waiting for a solution. *Ann Surg Innov Res* 2012;6(1):1-5
31. Pans A, Desaive C, Jacquet N. Use of a preperitoneal prosthesis for strangulated groin hernia. *Br J Surg* 1997;84(3):310–12
32. Wysocki A, Pozniczek M, Krzywon J, Bolt L. Use of polypropylene prostheses for strangulated inguinal and incisional hernias. *Hernia* 2001;5(2):105–6
33. D'Ambrosio R, Capasso L, Sgueglia S et al. The meshes of polypropylene in emergency surgery for strangulated hernias and incisional hernias. *Ann Ital Chir* 2001;75(5):569–73 (article in Italian)
34. Topcu O, Kurt A, Soyulu S, Akgol G, Atabey M, Karakus BC, Aydin C. Polypropylene mesh repair of incarcerated and strangulated hernias: a prospective clinical study. *Surg Today* 2013;43(10):1140–4
35. Carbonell AM, Cobb WS. Safety of prosthetic mesh hernia repair in contaminated fields. *Surg Clin North Am* 2013;93(5):1227–1239
36. Slater NJ, Knaapen L, Bökkerink WJ et al. Large contaminated ventral hernia repair using component separation technique with synthetic mesh. *Plast Reconstr Surg* 2015;136(6):796e–805e
37. Warren JA ,Beffa LR , Carbonell AM , et al. Prophylactic placement of permanent synthetic mesh at the time of ostomy closure prevents formation of incisional hernias. *Surgery* 2018;163:839–46 .
38. MaggioriL ,Moszkowicz D , Zappa M , et al. Bioprosthetic mesh reinforcement during temporary stoma closure decreases the rate of incisional hernia: a blinded, case-matched study in 94 patients with rectal cancer. *Surgery* 2015;158:1651–7
39. Liu DSH ,Banham E , Yellapu S. Prophylactic mesh reinforcement reduces stomal site incisional hernia after ileostomy closure. *World J Surg* 2013;37:2039–45
40. Benlice C, Gorgun E, Aytac E, et al. Mesh herniorrhaphy with simultaneous colorectal surgery: a case-matched study from the American College of Surgeons National Surgical Quality Improvement Program. *Am J Surg* 2015;210:766-71
41. García-Ureña MÁ, López-Monclús J, Hernando LAB, et al. Randomized controlled trial of the use of a large-pore

- polypropylene mesh to prevent incisional hernia in colorectal surgery. *Ann Surg* 2015;261:876-81
42. Noback S, Rogmark P, Petersson U. Negative pressure wound therapy for treatment of mesh infection after abdominal surgery: long-term results and patient-reported outcome. *Scand J Surg* 2017;106(4):285–93
43. Pandey H, Thakur D S, Somashekar U, Kothari R, Sharma D. Use of polypropylene mesh in contaminated and dirty strangulated hernia short term results. *Hernia* 2018;22:1045-50.

Copyright © 2022 Journal of Research in Applied and Basic Medical Sciences

This is an open-access article distributed under the terms of the Creative Commons Attribution-noncommercial 4.0 International License which permits copy and redistribute the material just in noncommercial usages, provided the original work is properly cited.