Urmia University of Medical Sciences
RABMS
International Journal of Research in Applied and Basic Medical Sciences
ISSN: 2476-3624

Follicular growth and atresia and morphometric alteration of uterine tissue following letrozole administration in mature NMRI mice

Selda Zeinalivand[1*], Kazem Parivar[1], Nasim Hayati Roudbari[1]

[1] *Department of Biology, Science and Research Campus, Azad University, Tehran, Iran*

***Corresponding authors**: Selda Zeinalivand, **Address**: Department of Biology, Science and Research Campus, Azad University, Tehran, Ira*n*, **Email**: Selda.zv@gmail.com, **Tel**: +989144476217

Abstract

***Background & Aims*:** Letrozole, as an aromatase inhibitor drug, is administrated to induce ovulation in individuals with anovulation disorder and, at the same time, it is used to enhance pregnancy success. The current study was designed to investigate the effect of Letrozole on follicular growth/atresia, as well as uterine histology. For this purpose, 15 mature female NMRI mice were assigned into 3 groups (NO=5 in each group): Control, Control sham, which received double distilled water, orally and experimental group received 0.5 mg/kg letrozole, orally.

Materials & Methods: Following 14 days, the animals were euthanized and, the follicular number and percentage of atresia at different stages of growth and the morphometric changes of uterine tissue were analyzed and compared between groups.

Results: The animals in experimental group represented no significant changes in primary, secondary, tertiary follicles, but exhibited a remarkable ($p<0.05$) reduction in graafian follicles number per two ovaries versus control and control-sham animals. Moreover, the letrozole -received mice exhibited diminished percentages of graafian follicles compared to control and control-sham animals. Finally, the endometrial thickness, as well as endometrial glands distribution per one mm^2 of tissue were decreased in experimental group when compared to control and control-sham animals. ***Conclusion:*** Letrozole significantly reduces the graafian follicles atresia and via this mechanism up-regulates the ovulation ratio. However, it is able to prolong uterine development during a menstrual cycle.

***Keywords*:** Letrozole, NMRI, Ovary, Ovarian follicles, Uterine

Received 09 Feb 2019; accepted for publication 29 May 2019

Introduction

Lastly, the fertilization potential of female individuals is diminished due to genetic disorders and/or environmental pollutions/agents. Generally, all these factors are able to result in temporal and/or complete infertility. For instance, polycystic ovarian syndrome (PCOS), as an endocrine disorder, potentially results in anovulation in pregnancy aged women (1). Likwise, types I and II diabetes, chemo and radiotherapies are known as other factors resulting in infertility (2, 3). Considering this fact, the ovulation induction by using various drugs and chemicals is used extensively in the field of assisted reproduction. In line with this issue, the clomiphene citrate is a first choice drug to induce

[Downloaded from ijrabms.umsu.ac.ir on 2024-10-12]

ovulation, and it is used widely in the field of assisted reproduction. Approximately 70% of patients represent ovulation, when received 50 and 100 mg/kg of clomiphene citrate. Meanwhile, in some cases, even 150 mg/kg of this drug is not able to induce ovulation. Thus, patients with negative response are known as "resistance patients" and alternative medications are used for these individuals (4). On the other hand, previous researches have reported the clomiphene citrate-related disorders both at embryo development and even in fertilization status of animal models (5). Therefore, the interests to the administration of alternative drugs with more efficiency and a lower side effect is growing day by day.

Letrozole is known as one of these agents (6, 7). It has been shown that letrozole, potentially, results in more oocyte delivery (better ovulation) and at the same time, exerts long protective profiles to preserve fertility in patients (8-10). Indeed, letrozole is an aromatase inhibitor, which reversibly attaches to the active site of the aromatase enzyme and prevents its activity. Letrozole, by suppressing the hypothalamus-pituitary-ovary axis, inhibits the local secretion of estrogen in the ovaries (11), but it does not affect the circulatory estrogen level (12). Recently, letrozole is also used to induce ovulation in patients with chronic unknown anovulatory disorders, with or without ovarian failure (13, 14). Among all identified effects of letrozole, the effect of this drug on follicular growth and its effects on the histological structure of the uterus is remained unknown.

Therefore, the current study is designed to evaluate the effects of letrozole on ovarian follicles (at different stages of development) growth and or atresia, as well as morphometric alteration of uterine histology, by using an animal model. For this purpose, total ovarian follicular reserve and atresia at different stages of growth were analyzed. Moreover, histomorphometry changes in uterine, including endometrium, myometrium, and perimetrium, as well as endometrial glands were investigated and compared between groups.

Method and materials

Experimental design and grouping:

In this study 15 female adult NMRI mice, 8-12 weeks and weighting between 28-30 g were used. All animals were kept in an environmentally controlled room (12h dark/12h light and 25±2 ^{0}C temperature) and received standard food and water ad libitum. The animals were assigned into three groups (No=5 in each group), including control, control-sham and experimental groups. A vehicle 0.5 mL of saline (0.85% w/v) was administrated to control-sham animals and the animals in the experimental group received 0.5 mg/kg letrozole for 14 days. All stages of the experiments were monitored by the Ethics Committee of the Islamic Azad University of Science Research Branch and were conducted in accordance with the rules of animal rights in the experimental research (NIH Publications No. 8023, revised 1978).

Tissue process and staining:

Following test termination, the animals were euthanized and the ovarian and uterine tissues were dissected out, fixed in 10% formalin fixative solution, routinely passaged and finally, paraffin embedded. Then, 5 mm serial sections were prepared using digital microtome (Historange-2218, Sweden) and stained H&E for analyzing histomorphometry changes using a light microscope (Olympus CH-13, Japan) at two 400X and 1000X magnifications.

Histological examination of ovarian tissue and follicular count:

To demonstrate the effect of letrozole on follicle population and atresia at different stages of development, the follicles were categorized into 4 groups of primary, secondary, tertiary and graafian. Then, the follicles were counted in both ovaries and compared between groups. The follicles with a complete layer of flattened granulosa and theca cells, oocytes with cytoplasm and a normal nucleus were considered as intact follicles. Atretic follicles were classified by defining granulosa cells dissociation, oocyte with heterogeneous cytoplasmic, early antrum formation, granulosa cells Latinization (especially in pre-antral follicles).

Uterine analyses:

[Downloaded from ijrabms.umsu.ac.ir on 2024-10-12]

In order to investigate the effect of letrozole on uterine tissue, the morphometric alterations, including uterine tube diameter, endometrium, myometrium and perimetrium thicknesses were evaluated by morphometric lens (Olympus, Japan). Moreover, the number (in one mm^2 of endometrium) and thickness of uterine glands were measured and compared between groups.

Statistical analyses:

The photomicrographs were taken by using SONY camera (Sony, Cyber-Shot, Japan). All results are presented as mean ± SD. Differences between quantitative data were analyzed with one-way ANOVA, followed by Bonferroni post-hoc test, using SPSS software (Version: 19.0, California). A P< 0.05 was considered as statistically significant. Photoshop software (CS10, USA) were used in order to processing and marking the photos.

Results

Alterations of atretic follicles and populations:

Histological analyses revealed that a total number of primary, secondary and tertiary follicles was not changed significantly in the experimental group compared to control and control-sham animals (Fig. 1). However, the total number of graafian follicles were remarkably decreased in the experimental group versus the control and control-sham animals (P<0.05). Animals in the experimental group exhibited a significantly lower percentage of atretic primary follicles versus control and control-sham animals. No significant changes were revealed in the percentage of atretic secondary follicles between all groups. the percentage of atretic tertiary and graafian follicles was significantly decreased in the experimental group. Figure 2 shows different development stages of atretic and normal follicles in ovaries (Fig. 2)

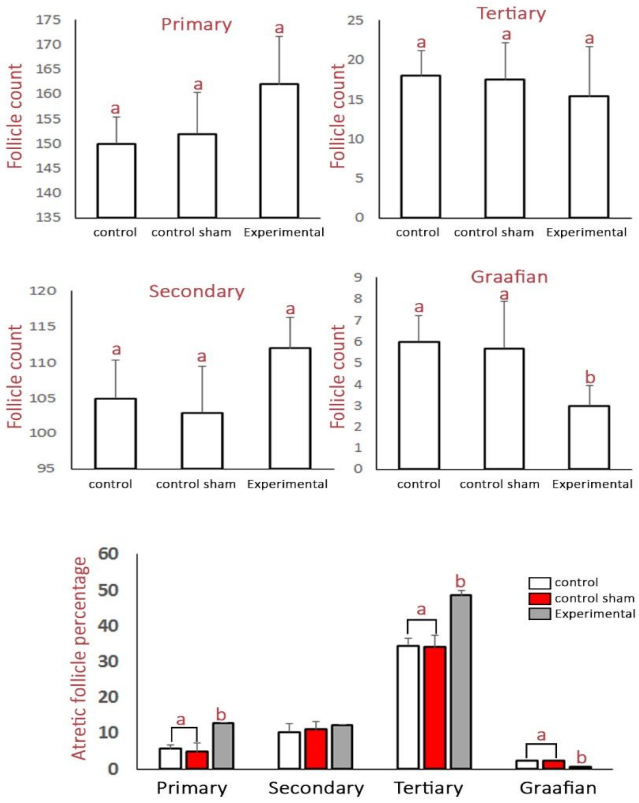

Fig. 1: General alterations of total follicles count and percentage of atretic follicles in ovaries of different groups. All data are presented in mean ± SD.

a vs. b; Significant at P<0.05.

[Downloaded from ijrabms.umsu.ac.ir on 2024-10-12]

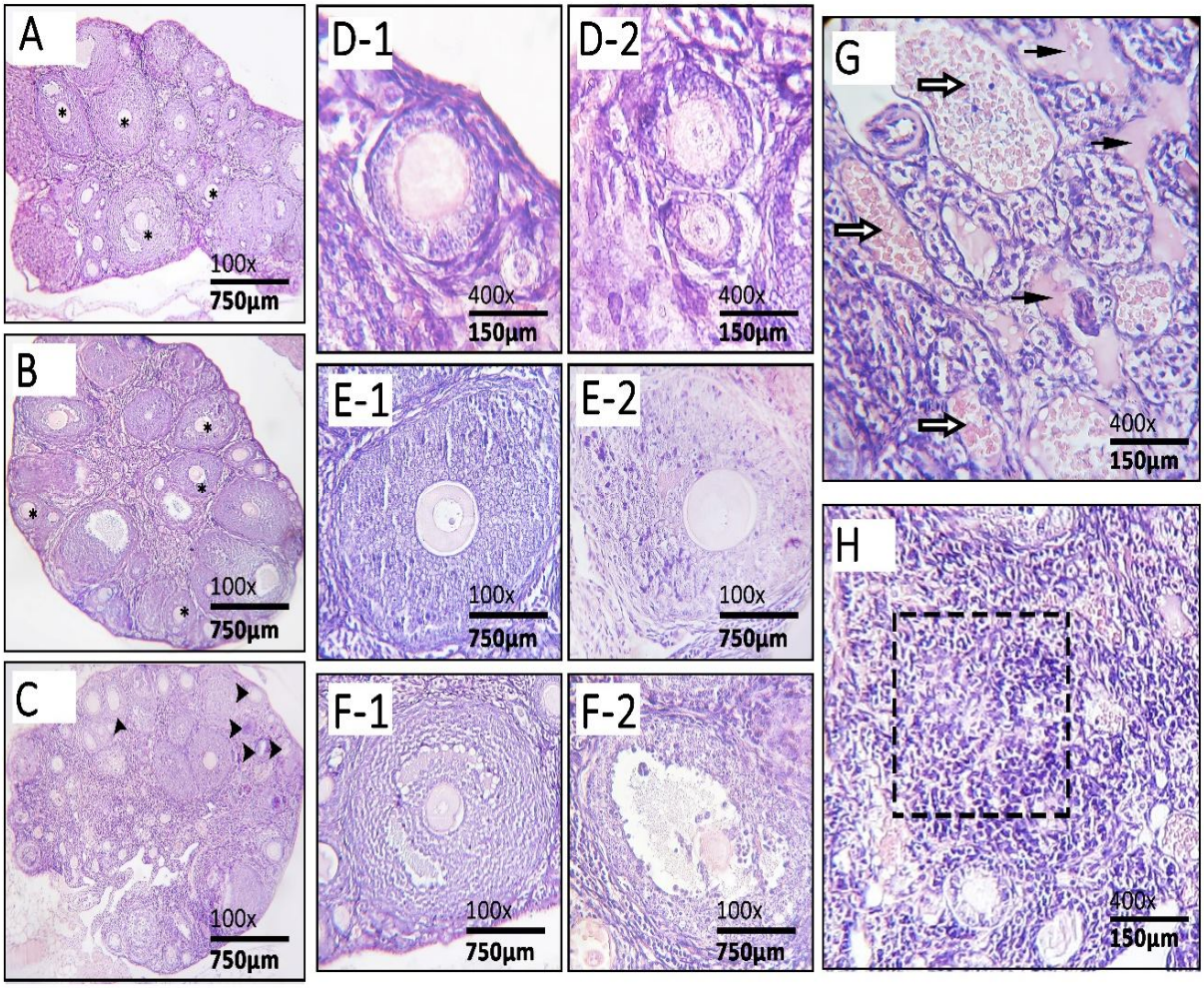

Fig 2. Cross sections from ovaries. A: control, B: control-sham and C: Experimental (letrozole-received). D-1 representing normal primary follicle, D-2 atretic primary follicle, E-1: normal secondary follicle, E-2: atretic secondary follicle, F-1: normal tertiary follicle, F-2: atretic tertiary follicle and G central zone of experimental group that representing congestion (white arrows) and edema (Black arrows) and section B performing infiltration of immune cells. Normal follicles and atretic follicles marking with stars and arrowhead, respectively, H&E staining.

Alteration of histological structure of uterine:

Morphometric analyses showed that perimetrium and endometrium thickness of uterine tissue was significantly decreased in experimental group versus the control and control-sham animals ($P<0.05$). Moreover, the histomorphometry changes in myometrium thickness and lumen diameter were not statistically significant between control, control-sham and experimental groups (Fig. 3). In addition, observations revealed that endometrial glands diameter was increased in experimental group. Meanwhile, the animals in experimental group represented a remarkable reduction in glands distribution per one mm^2 of tissue versus control and control-sham animals (Table 1).

[Downloaded from ijrabms.umsu.ac.ir on 2024-10-12]

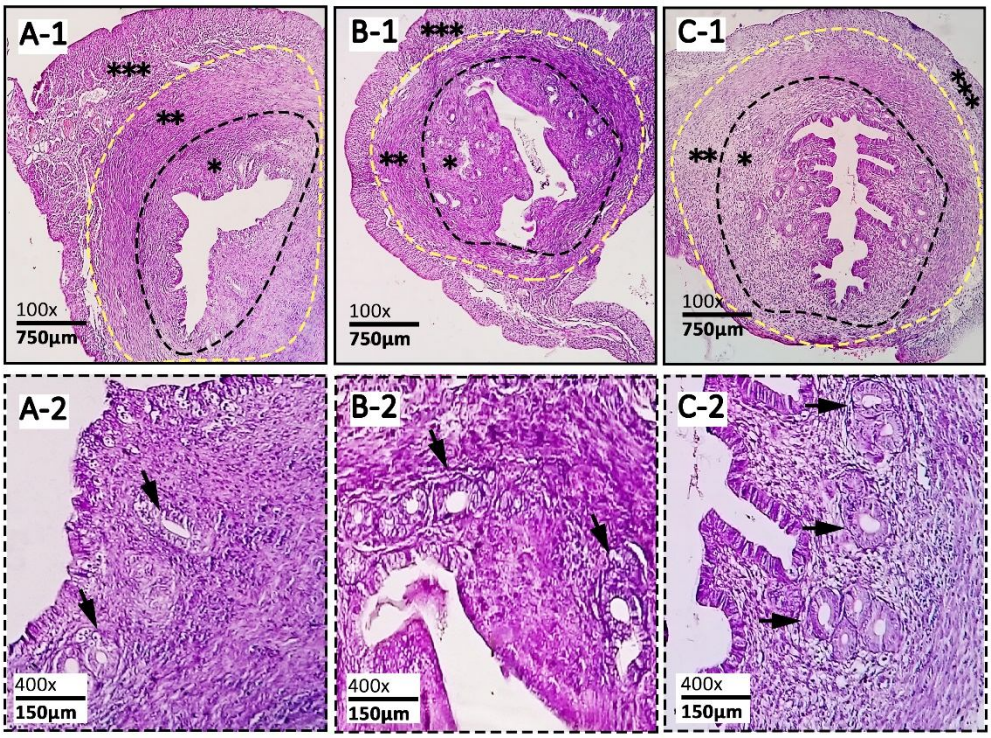

Fig. 3: cross sections of uterine. A: Control, B: Control sham and C: experimental groups. *: Endometrium, **: Myometrium and ***: Perimetrium. endometrial glands are presented with arrows (400X).

Table 1. Morphometric alterations of histological structure in different groups

	Control	Control Sham	Experimental
Uterus lumen (µm)	148±11/27	160±51/66	175/5±15/1
Endometrium (µm)	345±25/78	314±31/66	248±20/21
Myometrium (µm)	130±18/26	124±10/87	143±17/26
Perimetrium (µm)	128±12/09	129±7/52	91±10/69
Uterus Gland Diameter (µm)	45±3/73	42±2/66	61±9/2
Total count of Glands	27/6±2/38	25/2±2/09	20/4±2/23

All data are presented in mean ± SD. a vs. b; Significant at $P<0.05$.

Discussion

Due to the widespread administration of letrozole to induce ovulation in anovulatory problems, medication side effects or its possible impact on the reproductive potential of individuals, particularly the growth of ovarian follicles, has attracted the interest of many researchers. Based on this fact, in the current study, the histological changes of the ovaries and the growth and/or atresia of the ovarian follicles in letrozole-received mice were compared with intact control animals (without intervention) to determine the effects of the letrozole on ovarian follicular reserve. Minding the physiological correlation between ovarian and uterine tissues, the morphological changes of the uterine tissue were examined and compared with the control group. Observations showed that the number of the primary and secondary follicles in the experimental group (letrozole-received) was increased versus the control and control-sham animals. However, this increment was not significant in the statistical analysis.

[Downloaded from ijrabms.umsu.ac.ir on 2024-10-12]

About tertiary and graafian follicles, no significant change was revealed in the number of tertiary follicles between all groups. However, the animals in the experimental group (letrozole-received) exhibited a significant reduction in the number of graafian follicles compared to control and control-sham animals. About histomorphometry changes of the uterine wall, the diameter of endometrium and perimetrium was decreased in the experimental group (letrozole-received) compared to the control and control-sham animals. Moreover, the endometrial glands diameter and number *per* one mm^2 of tissue were significantly diminished in the experimental group. To understand the mechanism by which letrozole affects follicular growth and/or even ovulation, one should note sex hormones and the network between pituitary and ovary, as well. In line with this issue, Allaway et al., recently showed that administration of letrozole up-regulates the serum FSH and LH levels (15). Minding the critical role of FSH on pre-antral follicles development (16), it is logical to suggest that letrozole, by stimulating hypophysis, initiates and stimulates primary and secondary follicles growth and development.

Observations revealed that letrozole enhanced the number of primary and secondary follicles compared to the control and control-sham animals. But, as an interesting point, this increment was not statistically significant. To better understand this issue, it should be noted that increased FSH secretion will be effective only when the follicular population of the ovary is determined in a predisposition and the majority of the follicular population is presented in pre-antral stage (15). It means that, due to a short menstrual cycle in animals models (5-6 days), they represent the follicular development process faster than humans (17). Therefore, based on the time considered in the current trial (2 complete menstrual cycle), the follicular growth may have expedited under letrozole impact, and through this mechanism, the majority of the follicles in initial phases could pass into developmental stages (antral and/or graafian) at the first cycle. Therefore, lower population (especially primary and secondary) of pre-antral follicles were detected at second menstrual cycle. However, it should be considered that the number of primary and secondary follicles insole, does not indicate ovarian function and the changes at the antral follicle level should be evaluated, as well. In this regard, our findings showed that the number of the tertiary follicles in the experimental group (letrozole-received) did not change compared to the control and control-sham animals, but the number of graafian follicles was decreased. In addition, to evaluate the ovarian function, the percentage of atretic follicles was estimated and compared between groups. Observations showed that the percentage of tertiary and graafian follicles was significantly decreased in the experimental group (letrozole-received) compared to the control and control-sham animals. Considering that the number of tertiary follicles in the experimental group was not significantly different from that of the control and control-sham animals, and even the number of graafian follicles in the experimental group was lower versus the control and control-sham animals, it can easily be concluded that, despite the lower number of antral follicles, letrozole was able to reduce follicular atresia and even increase follicular survival.

Along with this study, previous studies have shown that letrozole stimulates the pre-antral and antral follicles growth and increases ovulation, as well (15, 18, 19). Therefore, it can be concluded that letrozole is initially able to up-regulate the growth wave of ovarian follicles in a single menstrual cycle by stimulating the growth of pre-antral follicles and reducing the antral follicles (especially graafian ones) atresia, and via this mechanism, it is able to enhance ovulation. But it will not be amiss if it is pointed out that administration of letrozole reduces serum estrogen (albeit, in a menstrual cycle) (15, 20). Considering that Graafian follicles and to a lesser extent other follicles are involved in ovarian estrogen synthesis, it can be noted that since the number of graafian follicles decreases following the administration of letrozole, serum estrogen levels will consequently decrease.

In continue, due to the physiological relationship between ovarian and uterine tissues, the morphological changes of uterine layers, as well as uterine glands, were

[Downloaded from ijrabms.umsu.ac.ir on 2024-10-12]

evaluated. To better understand the effect of letrozole on the histological structure of the uterus, it should be noted that the growth of the functional endometrial uterus is broadly estrogen-dependent. Thus, estrogen proliferates endometrial cells, develops endometrium and proliferates endometrial glands, which all of mentioned issues consequently develop with progesterone involvement (21).

Since letrozole is an aromatase inhibitor (22), and the synthesis of estrogen is largely depends on the aromatization pathway (23), thus any reduction in serum or even tropical Estrogen levels, naturally will be able to affect the histological structure of the uterus. Considering the above mentioned issues (firstly, reducing the number of adult follicles as estrogen sources, and the inhibitory effect of letrozole on the activity of aromatic enzymes), in the present study, endometrial thickness was evaluated in different groups. Observations showed that the thickness of the uterine endometrium and consequently the uterine cavity diameter were decreased and increased in the experimental group (letrozole recipient), respectively. Likewise, in the experimental (letrozole-received) group, the number of uterine glands was reduced compared to the control and control-sham animals. Therefore, it can be concluded that letrozole is able to alter the histological structure of the uterus in spite of its positive effect on follicular growth. This alone provides grounds for expressing that after treatment with letrozole, supplementary therapies should be considered in order to improve the uterine structure.

Conclusion

According to the results, letrozole stimulates the growth of the primary and secondary follicles and, in addition, reduces the percentage of atresia of tertiary and graafian follicles. Moreover, the effect of letrozole on the histologcript ical structure of the uterus was investigated, as well. Observations revealed that letrozole may delay the growth and development of the uterus despite stimulation of follicular growth. Therefore, letrozole is an ovulation-stimulating agent. However, supportive therapies for subsequent growth and development of uterine tissue is necessary.

References

1. Asuncion M, Calvo RM, San Millan JL, Sancho J, Avila S, Escobar-Morreale HF. A prospective study of the prevalence of the polycystic ovary syndrome in unselected Caucasian women from Spain. J Clin Endocrinol Metab 2000;85(7):2434-8.
2. Szaboova R, Devendra S. Infertility in a young woman with Type 2 diabetes. London journal of primary care 2015;7(3):55-7.
3. Kelnar CJH, Critchley HOD, Bath LE, Anderson RA, Wallace WHB. Hypothalamic–pituitary–ovarian dysfunction after prepubertal chemotherapy and cranial irradiation for acute leukaemia. Human Reproduction 2001;16(9):1838-44.
4. Fleming R, Hopkinson ZE, Wallace AM, Greer IA, Sattar N. Ovarian function and metabolic factors in women with oligomenorrhea treated with metformin in a randomized double blind placebo-controlled trial. J Clin Endocrinol Metab 2002;87(2):569-74.
5. Mitwally MF, Casper RF. Aromatase inhibition for ovarian stimulation: future avenues for infertility management. Curr Opin Obstet Gynecol 2002;14(3):255-63.
6. Partridge AH, Gelber S, Peppercorn J, Sampson E, Knudsen K, Laufer M, et al. Web-based survey of fertility issues in young women with breast cancer. J Clin Oncol 2004;22(20):4174-83.
7. Ben-Haroush A, Farhi J, Ben-Aharon I, Sapir O, Pinkas H, Fisch B. High yield of oocytes without an increase in circulating estradiol levels in breast cancer patients treated with follicle-stimulating hormone and aromatase inhibitor in standard gonadotropin-releasing hormone analogue protocols. Isr Med Assoc J 2011;13(12):753-6.
8. Oktay K, Buyuk E, Libertella N, Akar M, Rosenwaks Z. Fertility preservation in breast cancer patients: a prospective controlled comparison of ovarian stimulation with tamoxifen and letrozole for embryo cryopreservation. J Clin Oncol 2005;23(19):4347-53.
9. Turan V, Bedoschi G, Moy F, Oktay K. Safety and feasibility of performing two consecutive ovarian

[Downloaded from ijrabms.umsu.ac.ir on 2024-10-12]

stimulation cycles with the use of letrozole-gonadotropin protocol for fertility preservation in breast cancer patients. Fertil Steril 2013;100(6):1681-5.e1.

10. Kim J, Turan V, Oktay K. Long-Term Safety of Letrozole and Gonadotropin Stimulation for Fertility Preservation in Women With Breast Cancer. J Clin Endocrinol Metab 2016;101(4):1364-71.
11. Bilotas M, Meresman G, Stella I, Sueldo C, Baranao RI. Effect of aromatase inhibitors on ectopic endometrial growth and peritoneal environment in a mouse model of endometriosis. Fertil Steril 2010;93(8):2513-8.
12. Vercellini P, Somigliana E, Vigano P, Abbiati A, Barbara G, Crosignani PG. Endometriosis: current therapies and new pharmacological developments. Drugs 2009;69(6):649-75.
13. Pritts EA. Letrozole for ovulation induction and controlled ovarian hyperstimulation. Curr Opin Obstet Gynecol 2010;22(4):289-94.
14. Casper RF, Mitwally MF. Use of the aromatase inhibitor letrozole for ovulation induction in women with polycystic ovarian syndrome. Clin Obstet Gynecol 2011;54(4):685-95.
15. Allaway HC, Chizen DR, Adams GP, Pierson RA. Effects of a single 20 mg dose of letrozole on ovarian function post dominant follicle selection: an exploratory randomized controlled trial. J Ovarian Res 2017;10(1):6.
16. Francois CM, Petit F, Giton F, Gougeon A, Ravel C, Magre S, et al. A novel action of follicle-stimulating hormone in the ovary promotes estradiol production without inducing excessive follicular growth before puberty. Sci Rep 2017;7:46222.
17. Byers SL, Wiles MV, Dunn SL, Taft RA. Mouse estrous cycle identification tool and images. PLoS One 2012;7(4):e35538.
18. Bedaiwy MA, Mousa NA, Esfandiari N, Forman R, Casper RF. Follicular phase dynamics with combined aromatase inhibitor and follicle stimulating hormone treatment. J Clin Endocrinol Metab 2007;92(3):825-33.
19. Angel M, Ghose S, Gowda M. A randomized trial comparing the ovulation induction efficacy of clomiphene citrate and letrozole. J Nat Sci Biol Med 2014;5(2):450-2.
20. Lopez AM, Pruthi S, Boughey JC, Perloff M, Hsu CH, Lang JE, et al. Double-Blind, Randomized Trial of Alternative Letrozole Dosing Regimens in Postmenopausal Women with Increased Breast Cancer Risk. Cancer Prev Res (Phila) 2016;9(2):142-8.
21. Samsioe G. The endometrium: effects of estrogen and estrogen-progestogen replacement therapy. Int J Fertil Menopausal Stud 1994;39 Suppl 2:84-92.
22. Song H, Lu D, Navaratnam K, Shi G. Aromatase inhibitors for uterine fibroids. Cochrane Database Syst Rev 2013(10):Cd009505.
23. Gruber CJ, Tschugguel W, Schneeberger C, Huber JC. Production and actions of estrogens. N Engl J Med 2002;346(5):340-52.

[Downloaded from ijrabms.umsu.ac.ir on 2024-10-12]