



Morphometric Study of Gallbladder in Cadavers

Divya.C^{*1}, Ashwini.N.S², Sridevi.N.S³

¹ Associate Professor, Department of Anatomy, Sri Devaraj Urs Medical College, Kolar, Karnataka, India

² Associate Professor, Department of Anatomy, Sri Devaraj Urs Medical College, Kolar, Karnataka, India

³ Professor and Head of Department of Anatomy, Sri Devaraj Urs Medical College, Kolar, Karnataka, India

***Corresponding authors:** Dr.Divya.C, **Address:** Department of Anatomy, Sri Devaraj Urs Medical College, Tamaka, Kolar - 563101, India, **Email:** dr.divyac@yahoo.com, **Tel:** +919844102462

Abstract

Background & Aims: The gallbladder and biliary tract are structures that are in close proximity to the adjacent organs and can exhibit a variety of anomalies and anatomic variations. However, the literature on morphological variations of the gallbladder and their prevalence are limited. This study aims to identify various anatomical variations in gallbladder shape and position that should be considered for clinical implications, investigative procedures, radiological studies, surgical interventions, embryological explanations, and comparative anatomy. Aim of this study is to study the morphology of gallbladder in cadavers.

Materials & Methods: This study was done on 100 cadaveric liver and gallbladder specimens available in the Department of Anatomy, Sri Devaraj Urs Medical College, Kolar, India. Parameters such as maximum transverse diameter and maximum length were measured with help of metallic tape. Each specimen was studied for morphological variations. The observations were tabulated and analysed statistically.

Results: Gallbladder samples had length ranging between 3.3 and 12 cm, transverse diameter between 2.0 and 5.0 cm. The commonest shape observed in this study was pear shaped in 84% of cases. The length of gallbladder below the inferior border of liver varied between 0.4 and 2.5 cm.

Conclusion: The anatomic variations of the gallbladder and biliary tract are critical during their surgical procedures. The present study describes the different anatomic variations of human gallbladder and its clinical importance. This study will greatly assist surgeons in understanding the possible morphology of the gallbladder.

Keywords: Gallbladder, External Morphology, Cholecystectomy

Received 12 February 2022; accepted for publication 13 March 2022

Introduction

The gallbladder (GB) is a pear-shaped hollow and viscous organ, situated obliquely in a non-peritoneal fossa on the under surface of the right lobe of the liver,

and extends from the right end of porta hepatis to the inferior border of liver. It's dimensions are about 7 to 10 cm in length, maximum breadth being 3 cm and capacity is between 30 to 50 ml. The presenting parts of gallbladder are fundus, body, and neck (1).

The gallbladder and the biliary tract are structures in close connection with the adjacent organs and may show various anomalies and anatomic variations (2).

Gallbladder varies greatly in its size and shape. It may be duplicated, bifid, or sometimes absent. Gallbladder also varies in its position. Some of the abnormal positions include intrahepatic, retro hepatic, suprahepatic, retroperitoneal, anterior epigastric, floating, and transverse position (3). These variations are noticed frequently during imaging of gallbladder and during surgical procedures like laparoscopy and cholecystectomy. Therefore, in surgical settings, it is very important to know and understand the anatomy and different types of variations of the gallbladder and the biliary tract (4).

It is very much essential to have a basic knowledge regarding the development and normal anatomy of biliary tract, which gives us a better understanding of the anatomical and embryological anomalies. Refinements in operative and diagnostic techniques demand detail knowledge of different anomalies. As the laparoscopic cholecystectomies are increasing, clear knowledge of the gallbladder variations is critical. Nevertheless, the literatures regarding morphological variations of the gallbladder and their incidence are scarce.

These variations, while generally symptom-free, frequently lead to complications and therefore must be clinically correlated (5). Awareness of these anomalies will decrease morbidity, and re-exploration in such patients.

With the increasing use of interventional and diagnostic procedures, as well as laparoscopic cholecystectomy, the study of variation in the external morphology of the gallbladder has become increasingly important (6). The present study describes the different anatomic variations of human gallbladder and its clinical importance. This study will add to knowledge and create awareness among anatomists, radiologist, surgeons and gastroenterologist to be thorough regarding the normal and abnormal aspects of gallbladder.

Material & Methods

This study was carried out on 100 cadaveric liver and gallbladder specimens available in the Department of Anatomy, Sri Devaraj Urs Medical College, Kolar, India. Parameters such as maximum transverse diameter of gallbladder at the level of body, maximum length of gallbladder from tip of fundus to the neck of it, and the length of gallbladder below the inferior border of liver were measured with help of metallic tape graduated in centimetres. Each specimen was studied for morphological variations. The observations were tabulated and analysed statistically.

Results

Maximum Length of Gallbladder: Average length of gallbladder was found to be 10.2 cm. The smallest gallbladder was 3.3 cm in length and the largest had a length of 12 cm. 76% of gallbladders had length ranging between 7 and 10.5 cm (Table 1).

Table 1: Length of gallbladder

Length in cms	No of specimens	Percentage
<7	6	6%
7-10.5	76	76%
10.5-12	18	18%

Maximum transverse diameter of gallbladder:

Mean breadth of gallbladder was 3.46 cm. The shortest transverse diameter was 2.0 cm and largest was

5.0 cm. 68% of gallbladders had a maximum transverse diameter between 3 and 4.5 cm (Table 2).

Table 2: Breadth of gallbladder

Breadth in cms	No of specimens	Percentage
<3	18	18%
3-4.5	68	68%
>4.5	14	14%

Shape of Gallbladder:

The gallbladders were classified according to their shapes. Various shapes observed were pear shaped,

cylindrical shaped, hourglass shaped, irregular, and retort shaped, as shown in Table 3. The commonest shape found was pear shaped (84%).

Table 3: Shapes of gallbladder

SHAPE	No. of Specimens	Percentage
Pear	84	84%
Cylindrical	8	8%
Retort	4	4%
Irregular	2	2%
Hourglass	2	2%

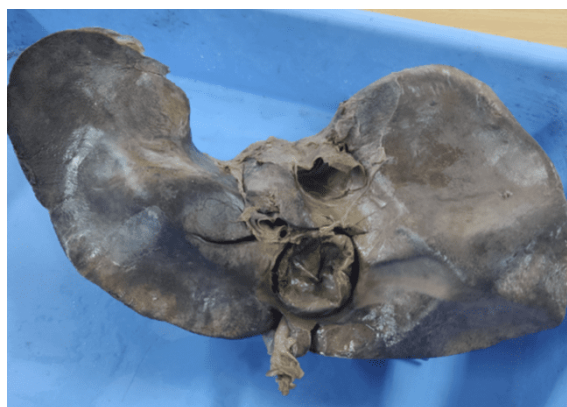External appearance of Gallbladder:

Foldings of neck and fundus (anteriorly or posteriorly) were noted. Folding of neck or fundus was noted in 6 out of 100 specimens of gallbladders.

Length of Gallbladder below Inferior Border of Liver:

The length of gallbladder below the inferior border of liver varied between 0.4 and 2.5 cm.

Figures 1 to 9 represent various anatomical shapes of gallbladder identified in this study. Figure 1 shows small, figure 2 large, figure 3 pear-shaped, figure 4 cylindrical, figure 5 flask-shaped, figure 6 hour-glass shaped, and figure 7 irregular-shaped gallbladders. Figure 8 represents folded fundus-phrygian cap and figure 9 shows Hartmann's pouch in gallbladder specimens.

**Fig 1:** Small gallbladder

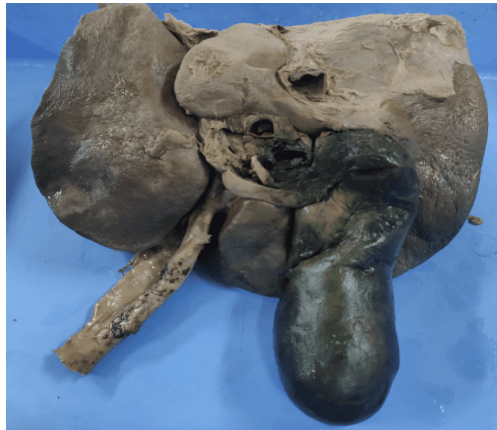

Fig 2: Large gallbladder

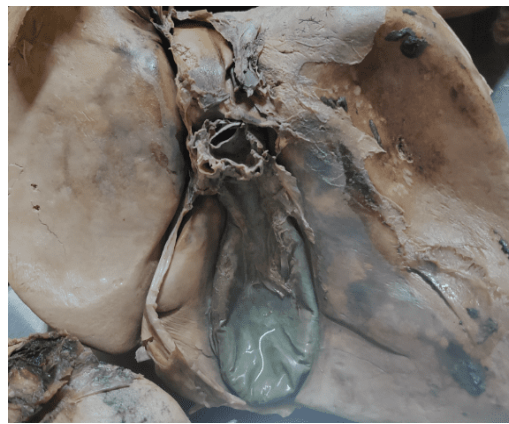


Fig 3: Pear-shaped gallbladder

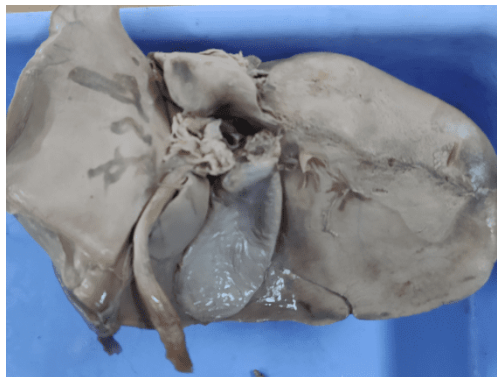


Fig 4: Cylindrical gallbladder

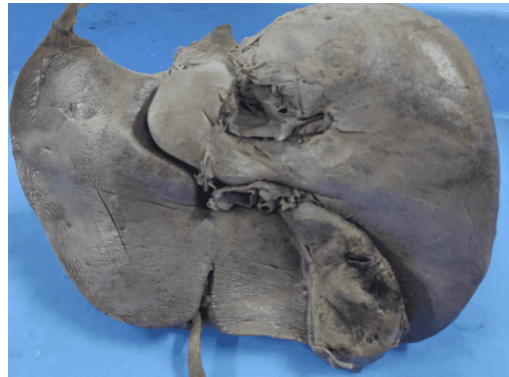

Fig 5: Flask-shaped gallbladder

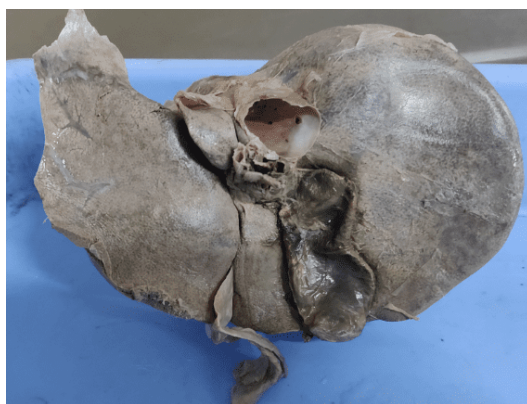


Fig 6: Hour-glass shaped gallbladder

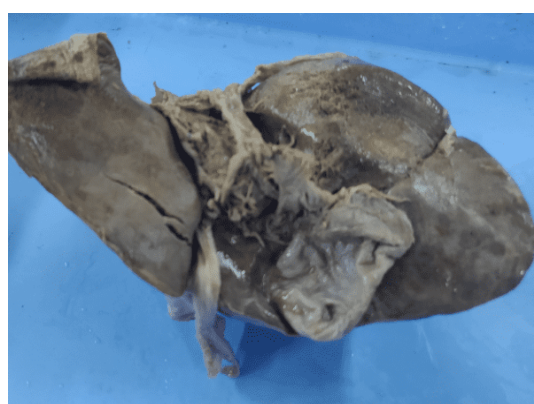

Fig 7: Irregular-shaped gallbladder




Fig 8: Folded fundus-phrygian cap

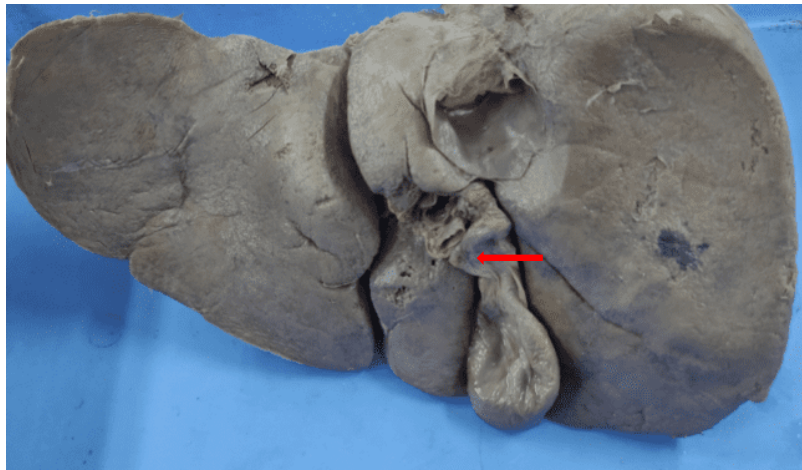


Fig 9: Hartmann's pouch

Discussion

As the laparoscopic cholecystectomies are increasing, clear knowledge of the gallbladder variations is critical. Surgeons must be aware of variations in the anatomy of the gallbladder, extrahepatic biliary system, and the arteries that supply them. Failure to recognise

them may lead to inadvertent ductal ligation, biliary leak, and strictures following laparoscopic cholecystectomy (7).

The gallbladder, liver, and the biliary ductal system develop from the hepatic endodermal diverticulum of the foregut at the beginning of the fourth week of

development. This diverticulum rapidly proliferates into the septum transversum and divides into two parts – the cranial part develops the liver and the bile ducts while the caudal part gives rise to the gallbladder and the cystic duct. Any interruption or deviation from the normal embryological development process may result in gallbladder and biliary system malformations (1).

The measurements of length and breadth of gallbladder in the present study are very similar to them measured by Chari et al. (8). Vakil et al. (9), and Prakash et al. (5). Comparisons of length, breadth and shape of gallbladder of present study with other researchers are shown in [table 4](#).

Table 4: Comparisons of incidence of length, breadth, shape of gallbladder in different studies

No	AUTHOR	LENGTH (cms)	BREADTH (cms)	DOMINANT SHAPE
1	Turner & Fulcher (10) (2000)	10	3-5	Elliptical
2	Chari & Shah(8) (2008)	7-10	2-5	Pear shaped
3	Vakil & Pomfret (9) (2008)	7-10	4	Pyriform shaped
4	JabaRajguru(11) (2012)	5-12	2.5-5	Pear shaped
5	Prakash AV(5) (2013)	7-10	2-5	Pear shaped
6	Rajendra R (12) (2015)	4-11	2.5-5	Pyriform shaped
7	Stuti Srivastava (13) (2019)	5.5-11	3–5.5	Pear shaped
8	Present study	7-10.5	2-5	Pear shaped

Size of gallbladder varies in different disease conditions as well as in some physiological conditions. It may be impossible sometimes to distinguish between various parts described. The size of gallbladder may increase after vagotomy, diabetes, pregnancy, sickle cell disease, and after cystic duct or common bile duct obstruction. Shapes of gallbladder vary tremendously and various authors have described various shapes. We found pear shaped gallbladder as most common in 84 cadavers. Jaba Rajguru et al. (11) noted pear shaped gallbladder in 85% of specimens.

The gallbladder is relatively constant in its development and the two most significant variations are the folded fundus and the variations at the neck of the gallbladder. The folded fundus of the gallbladder, also called as the Phrygian cap, is a triangular deformity of gallbladder fundus in which the fundus is folded on the body resulting in partial separation of the fundus from the body, and however is considered as a normal anatomical variant of gallbladder. It is caused by a localised thickening of the gallbladder wall, and is of little significance because the gallbladder function is

usually normal (14). In our study, we found folded fundus in 6 gallbladder samples (6%).

Hartmann's pouch is a diverticulum that can occur at the neck of the gallbladder. There is a significant association between the presence of Hartmann's pouch and gallbladder stones. Nadeem G. (15) reported Hartmann's pouch in 10% of gallbladder specimens, and in the present study, the incidence of Hartmann's pouch is 2%.

The length of gallbladder below the inferior border of the liver in our study was found to be ranging between 0.4 and 2.5 cm. This is the most susceptible part of gallbladder that can be damaged in laparoscopic procedures. Hence surgeons should be aware of these measurements.

Conclusion

In the present study on 100 gallbladder specimens, the findings showed various anatomical variations pertaining to gallbladder shape and position, which will help surgeons and interventional radiologists to understand and identify the possible variation of gallbladder. The study provides details of the anatomic

variations of the gallbladder and awareness of these anomalies is of considerable importance to radiologists to differentiate Riedel's lobe of the liver with the variations of the gallbladder. Furthermore, knowledge of variant anatomies of gallbladder is of greatest significance to laparoscopic surgeons during cholecystectomy to prevent disastrous consequences during surgery such as hepatobiliary injuries, hemorrhage and hemobilia. It also reduces morbidity and re-exploration in such patients.

Acknowledgement: Nil

Conflict of interest

The authors have no conflict of interest in this study.

Ethical Statement

This study was conducted on human cadaveric tissues obtained from the Department of Anatomy, Sri Devaraj Urs Medical College, Kolar, India. The use of these tissues was approved by the Institutional Ethics Committee of Sri Devaraj Urs Medical College. The tissues were handled with respect and care, following the guidelines of the Human Tissue Authority and the Anatomical Society. No personal or identifiable information of the donors was disclosed in this study.

References

1. Standerig S; Gray's anatomy: The anatomical Basis of clinical Practice, 40th Ed, Elsevier Churchill Livingstone, Philadelphia, London; 2008. pp 1177-81.
2. Moore KL, Dalley AF. Clinically oriented anatomy in abdomen, 5th edition, Philadelphia: Lippincott Williams & Wilkins; 2006:302.
3. Bergman RA, Afifi AK, Miyauchi R. Illustrated Encyclopedia of Human Anatomic Variation: Opus IV: Organ Systems: Digestive System and Spleen. Gallbladder; 2015:21.
4. Talpur KA, Laghari AA, Yousfani SA, Malik AM, Memon AI, Khan SA. Anatomical variations and congenital anomalies of Extra Hepatic Biliary System encountered during Laparoscopic Cholecystectomy. J Pak Med Assoc 2010;60:89-93.
5. Prakash AV, Panshewdikar PN, Joshi DS, Anjaankar AP. A cadaveric study involving variations in external morphology of gall bladder. Int J Med Res Health Sci 2013;2(2):239-42.
6. Sreekanth C, Kumari M T, Hema L. Variations in the external morphology of gall bladder: A cadaveric study in South coastal population. J Med Dent Sci 2016;15(9):14-20.
7. Nagral S. Anatomy relevant to cholecystectomy. J Min Access Surg 2005;1:53-8.
8. Chari RS, Shah SA. Biliary system In: Townsend CM, Beauchamp RD, Evers BM, Mattox KL. Sabiston Textbook of Surgery. 18th edition; St. Louis, Mo: WBSaunders; 2007: 1474-514
9. Vakili K, Pomfret EA. Biliary anatomy and embryology. Surg Clin North Am 2008;88(6):1159-74.
10. Turner MA, Fulcher AS, Gore RM, Levine MS. Textbook of Gastrointestinal Radiology in Gallbladder and Biliary: Normal anatomy. and examination techniques. 2nd ed vol 2. WB Saunders. Philadelphia, 2000;1250-76.
11. Rajguru J, Satyam K, Shilpi J, Rashmi G, Mukesh S, et.al. Variations in the external morphology of gall bladder. J Anat Soc India 2012; 61(1):9-12.
12. Rajendra R, Makandar U K, Tejaswi H L, Patil B G. Morphometric Study of Gall Bladder In South Indian Population (cadaveric study). Indian J Forensic Community Med 2015; 2(1):35-42
13. Stuti Srivastava, Abeer Zubair Khan. Morphology of Gall Bladder- A Cadaveric Study. Curr Med Res Opin 2019; 2(10): 293-8.
14. Piracci A, Mitrusi A, Totozani D. Ultrasound examination of anatomical variations of the gall bladder. Albanian Med J 2013; 1:88-91.
15. Nadeem G. A study of the clinico-anatomical variations in the shape and size of gallbladder. J Morphol Sci 2016; 33(2): 62-7.